

2D-3D Fusion Imaging (US & CT/MR): Interventional US Applied to Liver RF ablation

S. De Beni², M. Grimm¹, M. Maccio², G. Sakas¹, L. Solbiati³

¹MedCom GmbH, Darmsadt, Germany

²Esaote spa, Genoa, Italy

³Hospital Busto Arsizio, Italy

Image guidance is essential in the treatment of liver tumours using percutaneous ablative techniques. Apart from careful pre-procedure planning and elaborate post-procedure evaluation, accurate intra-procedure targeting, monitoring, and controlling play a critical role in the success of the technique.

Radiofrequency (RF) ablation is most commonly performed under ultrasound (U/S) guidance, with computed tomography (CT) guidance being reserved for lesions inconspicuous on US. However, there are occasions when the liver lesion is only optimally visualized on contrast-enhanced CT, making targeting and monitoring difficult due to lack of real-time imaging guidance. In this scenario, it would be desirable to co-register information from different imaging modalities (e.g., US and CT) and such multimodality matching have been utilized in nuclear medicine, radiotherapy, and neurosurgery.

NaviSuite® Virtual Navigator System

The system consists of an Esaote U/S scanner integrated with the Navigation unit (Fig 1). The US system provides the US image and its characteristics such as the spatial dimension, orientation and a probe fields of view. This permits a right representation in size and orientation of the second modality image. These data are provided by the US scanner by the network connection and automatically updated at every change on the console of the scanner. The US image is provided through the video signals and digitalized by a standard frame grabber in order to be presented beside the virtual one.

An electromagnetic tracking system, composed by an transmitter and a small receiver (mounted on the US probe) provides the position and orientation of the US probe in relation to the transmitter. The Electromagnetic Tracker works even if a medical tool is located between the transmitter and the receiver and it can be easily placed in any environment -- furthermore the cost is acceptable. A disadvantage of the magnetic principle is the sensitivity concerning metallic objects close or near the receiver or transmitter. It has been found during the clinical tests that this requirement can be achieved without affecting the clinical routine in noticeable way.

Registration between patient anatomy and its CT data can be done by a number of ways: by fiducial markers in the CT, by clicking anatomic markers, by manually shifting the CT and US images until registration appears acceptable, or by a fully automated method employing mutual information registration. During navigation the system extracts in real time an oblique CT slice at the location and orientation parallel to the U/S image, both images are displayed on the screen. Overlapping of the CT and US image enables quick and intuitive test of the registration accuracy (Fig 3). Additional interventional aids include the display of biopsy line in US and CT, (magnetic) tracking of the position of the needle, delineating and marking targets in CT visible in U/S, and display of RF ablation area and/or treated volume (Fig 2).

In conclusion real-time registration and matching of pre-procedure CT volume images with intra-procedure US is feasible and accurate. For simple biopsies, an experienced interventionalist will not ask for such a guidance tool and, given the cost and availability, US and CT guidance will remain the "workhorses" for biopsy procedures. For lesion hardly visible at US or CT or for more complex procedures, such as thermal tumor ablations that require positioning of multiple applicators and puncture of multiple lesions, navigation systems might be of help to reduce puncture risk and procedure time and to allow for more complete and radical therapy.



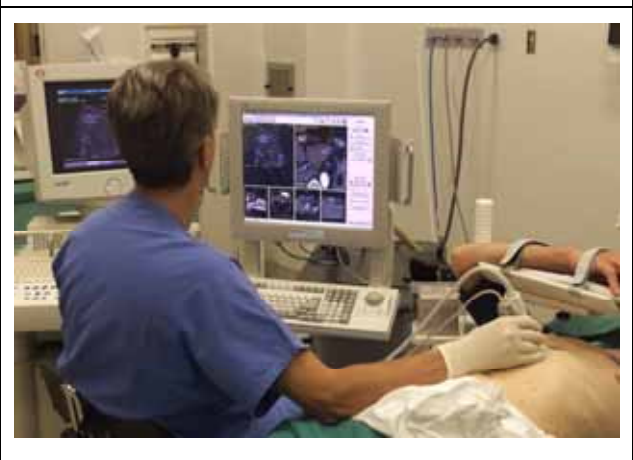
RESULTS

After some experience in setting up the navigation system we were able to perform the system setup including the registration within 3-5 min. CT-US registration is reliable with a mean registration error of

3mm ± 1 mm. The needle-to-target distance is 1.8 ± 0.8 mm. Thus accuracy is very good and sufficient for clinical routine.

In 87 patients with liver carcinoma and cirrhosis (51) or liver metastases of colorectal origin (36), 175 malignant tumours identified with multilayer CT were subjected to percutaneous radiofrequency thermal ablation using a real time image fusion system linking volumetric CT scanning with B-mode ultrasound. 96 of 175 (54.9%) tumours were poorly (69) or completely (27) invisible to ultrasound. The results of the treatment (centring precision and size of necrotic area with respect to size of tumour) were verified after 24 hours with CT multilayer scanning using contrast agent. Complete ablation was achieved in 165 of 175 (94.3%) tumours and, notably, in 65 of 69 (94.2%) of tumours with poor ultrasound visibility and 24 of 27 (88.9%) of those completely invisible to ultrasound. There were no major complications (Fig 4).

The main limitations are that the system cannot distinguish differences in respiratory excursion and subject motion, To extrapolate the utility in routine clinical practice, precise registration of CT volume images into the patient required proper synchronisation with respect to the respiratory phase and arms' position during CT examination, and patient movement must be avoided. Possible solutions for detection of patient movement would be the implementation of external electromagnetic position sensors to the patient's body. The solution could be based on methods used in radiation therapy, as well as on those used in positron emission tomography–CT image fusion

	
<p>Fig 1: U/S device with integrated NaviSuite</p>	<p>Fig 2: Interventional aids</p>
	
<p>Fig 3: Overlapping US and CT, biopsy guideline</p>	<p>Fig 4: Performing RF ablations</p>