

# BiopSee<sup>®</sup> – transperineal stereotactic navigated prostate biopsy

Pawel Zogal, MSc<sup>1</sup>, Georgios Sakas, MSc<sup>1</sup>, Woerner Rösch, MSc<sup>2</sup>, Dimos Baltas, MSc, PhD<sup>3</sup>

<sup>1</sup>MedCom GmbH, Darmstadt, Germany, <sup>2</sup>Gesellschaft für Medizintechnik mbH, Darmstadt, Germany, <sup>3</sup>Department of Medical Physics and Engineering, Klinikum Offenbach GmbH, Germany

## Abstract

In the recent years, prostate cancer was the most commonly diagnosed cancer in men. Currently secure diagnosis confirmation is done by a transrectal biopsy and following histopathological examination. Conventional transrectal biopsy success rates are rather low with ca. 30% detection upon the first and ca 20% after re-biopsy. The paper presents a novel system for stereotactic navigated prostate biopsy. The approach results into higher accuracy, reproducibility and unrestricted and effective access to all prostate regions. Custom designed ultrasound, new template design and integrated 2-axes stepper allows superior 2D and 3D prostate imaging quality and precise needle navigation. DICOM functionality and image fusion enable to import pre-operative datasets (e.g. multiparametric MRI, targets etc.) and overlay all available radiological information into the biopsy planning and guiding procedure. The biopsy needle insertion itself is performed under augmented reality ultrasound guidance. Each procedure step is automatically documented in order to provide quality assurance and permit data re-usage for the further treatment. First clinical results indicates success rates of ca. 70% by first biopsies by our approach.

J Contemp Brachyther 2011; 3, 2: 91-95

DOI: 10.5114/jcb.2011.23203

**Key words:** prostate cancer, navigated biopsy, image fusion, ultrasound, magnetic resonance imaging.

## Introduction and state of the art

The prostate cancer accounts for 25% of all male cancer occurrences and 9% of the cancer death causes in the European Union. [1]. Only in 2008, it was the most commonly diagnosed type, accounting for 25% of all cancers [2]. In Germany, there are about 58,000 prostate cancer diagnoses each year [3].

As for each cancer type, early diagnosis is extremely important in increasing the treatment effectiveness. Currently, several types of examination are used for screening potential patients: prostate specific antigen (PSA) test, digital rectal examination (DRE) and transrectal ultrasound (TRUS). Those methods however, are not sensitive enough and the only secured diagnosis is the prostate biopsy with following histopathology examination.

At present, the biopsy procedure is done with the help of transrectal 2D ultrasound. The probe is introduced to the patient's rectum and free-hand navigated by the doctor. The probe is equipped with a needle guide through which a needle is inserted after having established desired probe position towards the prostate area. The first publications in this area recommended a 6 core systematic biopsy [4], but later studies showed that the number was insufficient [5, 6]. Currently, the recommendation of the European Urology Association is at least 10 cores, whereas the exact

number shall be adjusted according to the PSA level and prostate volume [1].

Because of the fact that early cancer stages are invisible in the ultrasound images, the urologists are forced to take random biopsies without targeting specific cancer areas. This needs a mean of assurance that desired random distribution has been achieved. The biopsy procedure is limited by the 2D imaging, soft consistency and deformability of the prostate and instability of the manual probe navigation. These factors significantly reduce the positioning accuracy and permit a reproducibility of the biopsy needle guidance. The documentation of the biopsy core location is a highly insufficient process.

Thus, the success rate of the standard 12-core TRUS biopsy is ca. 30%. As a result, in around 40% of cases [7-9] a re-biopsy is needed. This happens when the PSA level increases in spite of negative result of the first biopsy. In the second examination, so-called saturation biopsy is performed with 20-40 cores again at random positions. In such circumstance, the doctor ideally has to avoid taking the probes from the places that have been verified earlier as negative. With current standards the information is deficient in order do so. Today, one tries to compensate the inaccuracy by an increased number of following cores, which in fact, increases patient's burden as well.

**Address for correspondence:** Pawel Zogal, MedCom Gesellschaft für Medizinische Bildverarbeitung mbH, Rundeturmstrasse 12, 64283 Darmstadt, Germany, phone: +49-6151-95147 15, fax: +49-6151-95147 20, e-mail: pzogal@medcom-online.de

Received: 05.05.11

Accepted: 20.06.11

Published: 30.06.11

Alternative approaches like MRI-based techniques are developing fast and are truly promising [2], but they are much more expensive in comparison to an ultrasound and severely more time and resources consuming in terms of time pro biopsy core taken.

### Advances by the presented contribution

Recent developments in morphologic, metabolic and physiologic 3D imaging – typically MRI-based – are showing very good prospects for tumour localization within the prostate. Unfortunately, those technologies are expensive (about 2-3 million € investment for a single site needed) and their real-time capability is very restricted. Further, they provide a good localisation of suspicious lesions, however give no guidance to stereotactical biopsy of these locations. To overcome these problems and increase biopsy success rate, we introduced a device combining every usable imaging information along with real-time ultrasound. The general idea is to use imaging to localize areas suspected of cancer and ultrasound to guide biopsy needles precisely to exactly those areas.

In our approach the user can fuse intraoperatively acquired 3D ultrasound on one hand with preoperatively acquired modalities, such as multi-parametric MRI, PET, SPECT or any other 3D dataset available in DICOM format to denote suspicious lesions and plan a targeted biopsy. The usage of the digital integrated ultrasound greatly improves 2D and 3D image quality. The real-time augmented reality ultrasound guidance improves greatly biopsy accuracy and reduces navigation time. The system also provides means for the procedure documentation which is essential in follow-up examinations and some novel treatment methods like brachytherapy and focal therapy of the prostate [10]. Additionally, by using the transperineal

approach one reaches every prostate area, minimizes deformation, maximises reproducibility and reduces the risk of infection associated with bacteria from the rectum infiltrating the prostate during the rectal insertion process [11]. A summary of the risks present during the conventional transrectal biopsy can be found in [12].

### Material and methods

#### *System architecture*

The presented device consists of a cart with a touch-screen and a PC with integrated ultrasound device and additional electronics for controlling position and orientation of the ultrasound probe. The probe itself is a custom bi-plane endorectal design that is optimized for biopsy process: longer shaft optimized mechanical design, 165° transversal and 75 mm longitudinal field of view. Each of the arrays consists of 128 elements, the maximum available frequency is 8 MHz for the transversal plane and 10 MHz for the longitudinal one. This accounts for delivering superb quality images, which are also additionally filtered by the software. The result is U/S images with de facto the best diagnostic quality available today.

During the procedure, the probe is placed in a mechanical custom-made fixation device called the stepper. This is a 2DoF set up: one can adjust probe depth within the patient's rectum and the rotation of the probe along its main axis. Both movement and rotation are tracked by 2 encoders which are connected to the aforementioned electronics inside the PC. The movement resolution is 0.1 mm and 0.1° for the rotation, respectively. The stepper itself is fixed to the operation table. As a result, one can image any plane of the prostate with very high accuracy and reproducibility, a fact impossible in the free-hand movement of the probe.

For the needle insertion part we developed a dedicated movable needle guide that is attached to the stepper. It has adjustable X and Y coordinates enabling to drive a needle with mm accuracy to any location within the prostate. The whole hardware set up is principally similar to the one used in a brachytherapy procedure, which gives the advantage that one could reuse certain equipment in both diagnosis and therapy. However, our new positioning device allows among others to pinpoint any position within the prostate without gridding truncations. However, the software supports also any kind of templates like those usually employed in brachytherapy procedures.

On the software side, the system design is modular. There is a kernel environment and each functional procedure step is mapped within a separate software module. Those include: ultrasound device control, U/S image filtering, stepper encoder control, U/S data acquisition, DICOM data interface, volume fusion, contouring, biopsy planning, guiding, reporting and the dedicated patient database.

#### *Workflow*

The user is free to perform different actions within the system, though a typical workflow for the navigated biopsy can be recommended and presented here. The pro-



Fig. 1. The BiopSee® cart with the stepper fixation



Fig. 2. The one-hole needle guidance device

cedure can be split into planning the biopsy and guided removal of the tissue cores.

In the first phase image, the data is acquired and respective organs and regions are delineated and marked. One can import different DICOM image modalities and fuse them with on-board 3D ultrasound. 3D U/S is acquired by recording a series of transversal or longitudinal 2D images while rotating or moving the probe along the Z direction, resulting very similar dataset to CT scans, however generated with ultrasound instead of X-rays. Additional imaging modalities, typically multiparametric MRI are imported through the DICOM interfaces. Both 3D volumes are then fused together using one of many available methods: manual, marker based or automatic [13]. This allows transferring organ and lesions usually visible on the diagnostic MRI scan and delineated by a radiologist over the intra-operative ultrasound dataset.

Finally, biopsy cores are placed virtually within the 3D data manually or automatically according to a pre-defined protocol. The experience shows that doctors use predominantly a combination of stereotactic target based and statistical biopsy. Once a biopsy plan has been established, the first phase of the approach is completed typically within 10-15 minutes.

During the following second (navigation) phase the user selects the desired biopsy core and first navigates the ultrasound probe to that position, i.e. the U/S transducer rotates until the longitudinal plane crosses the needle insertion line. Next, the needle guide template is set to




Fig. 3. The stepper-probe set-up

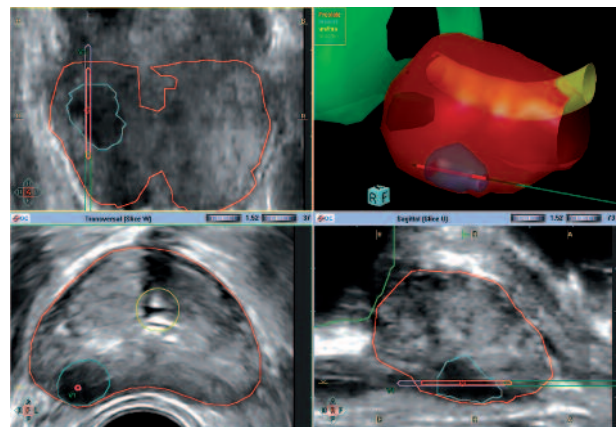


Fig. 4. A 3D U/S dataset with contoured structures and a planned biopsy inside a marked lesion

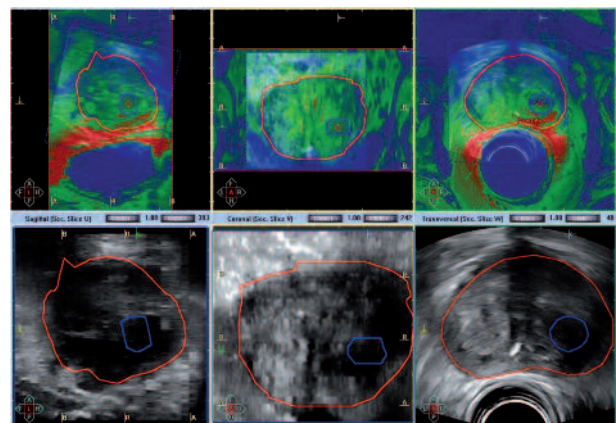


Fig. 5. Image fusion with mixed images (MRI - U/S) in the top row and ultrasound only in the bottom row

the planned coordinates by adjusting the X and Y coordinates by the values given by the planning tool. Last, the physician inserts the needle under continuous longitudinal ultrasound guidance.

The U/S image is overlaid by the organ and lesion contours as well as the planned needle position, thus a real-time navigation is established in a way that deviations from the

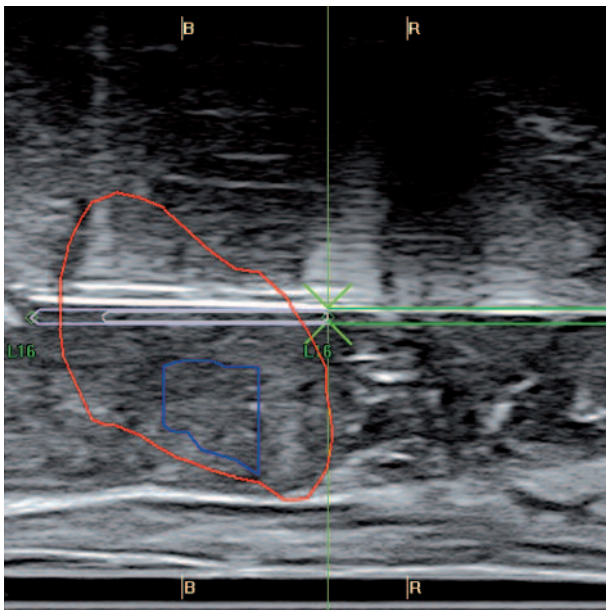


Fig. 6. An example of a longitudinal ultrasound image with the guiding overlay. The inserted needle is slightly off the planned one for demonstration purposes

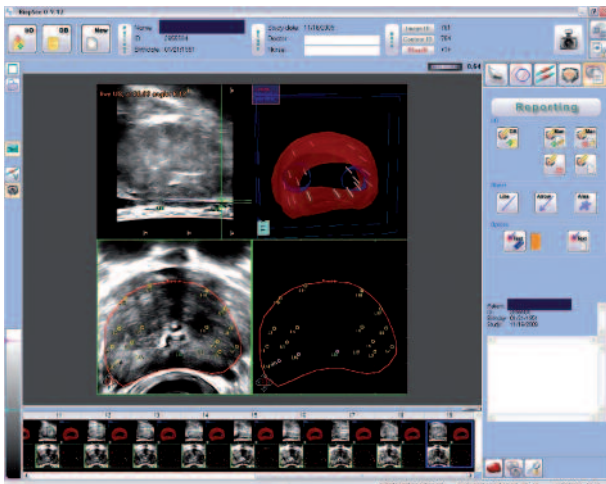


Fig. 7. Automatic documentation of each core

target become immediately visible on the screen and can be corrected on-the-fly, enabling a positioning of the needle by very high accuracy of few mm from the desired target position. Organ shifts caused by the tissue deformation during needle insertion are equally visible and can be adjusted manually if necessary. After each needle insertion, a screenshot is made and stored together with the position and orientation data for documentation purposes.

### Documentation

Documenting the procedure is an essential feature for follow-up examinations and treatment. The presented system has a custom designed patient database which allows saving any type of data used within the procedure. Our approach is the only one enabling complete and au-

tomatic documentation of the procedure without any user interaction. All information (images, contours, targets etc.) can be exported via DICOM-RT protocol to the therapy RTP system.

### Results

During the biopsy procedure one can mark the real needle position on the live ultrasound image. In order to measure the positioning accuracy, reconstructed needles are stored and their positions are compared to the planned ones. The preliminary assessment was comparing the distances between middle points of reconstructed biopsy cores and the planned ones. Within a dataset of 1159 needles reconstructed during the first 50 biopsy procedures, the calculated mean error was 1.7 mm. With conventional transrectal biopsy such assessment is not possible.

Results with the first 50 patients (submitted for publication) have been performed for a typical cohort (PSA  $9 \pm 7$ , prostate  $51 \pm 24 \text{ cm}^3$ , age 42-77). A saturation biopsy with an average of 24 cores was performed. In addition to the random cores, stereotactic samples have been taken from MRI suspicious areas. Cancer could be detected in 68% of the cases of first-time biopsies and 36% of re-biopsy after 1-3 initial negative 12-core TRUS biopsies. The average time for the procedure was 25 minutes.

In addition to the high detection rates, the principal benefit of our approach is its accuracy and reproducibility. Accuracy is needed for validating the MRI findings and, thus, the MRI method itself. Reproducibility means that since we track the needle location within the prostate accurately and we can reach effectively any prostate region, the biopsy cores are obtained guaranteed from different regions and by a regular scheme ensuring correct statistic coverage of the complete organ. This is important in the case of repeated biopsy procedure: new cores can be taken from areas where no needle has been placed in the first procedure. Also, our method is of fundamental importance for focal therapy approaches in excluding multi-focal or non-visible lesions on the opposite prostate gland.

### Conclusions

We presented a novel system for navigated prostate biopsy, which takes advantage of several computer graphics methods to enhance the examination procedure. The image fusion along with different visualization modes enables easier organ and target lesion delineation and thus effective biopsy planning and exact and reproducible core samples under automatic documentation. Our experience shows that the needle and probe navigation feature together with combining live ultrasound imaging with virtual objects is essential for accurate and reproducible needle insertion. The system has been clinically tested at the Offenbach Clinic and at the Heidelberg University Hospital. Tests in both hospitals with over hundred of patients confirmed the advantages of the image guided stereotactic prostate biopsy [14]. The implemented DICOM RT protocol for transferring the biopsy cores localisation, enables treatment planning systems to consider these locations for local dose escalation protocols (dose painting).

## References

1. Heidenreich A, Aus G, Bolla M et al. European Association of Urology "EAU" Guidelines on Prostate Cancer. *Eur Urol* 2008; 54: 693-695.
2. Hambrock T, Somford DM, Hoeks C et al. Magnetic Resonance Imaging Guided Prostate Biopsy in Men With Repeat Negative Biopsies and Increased Prostate Specific Antigen. *J Urol* 2010; 183: 520-528.
3. Robert Koch Institut. Gesundheitsbericht des Bundes: Krebs in Deutschland 2003-2004, Häufigkeiten und Trends (German government cancer report) 6. Auflage, 2008.
4. Hodge KK, McNeal JE, Terris MK et al. Random systematic versus directed ultrasound guided trans-rectal core biopsies of the prostate. *J Urol* 1989; 142: 71-74.
5. Van der Kwast TH, Hoedemacker RF, Krause R et al. Incidence of high grade intraepithelial neoplasia and suspect lesions in systematic sextant prostate needle biopsies in a population based screening study (ERSPC). *J Urol* 1998; 159: 180, abstract #689.
6. Norberg M, Egevad L, Holmberg L et al. The sextant protocol for ultrasound-guided core biopsies of the prostate underestimates the presence of cancer. *Urology* 1997; 50: 562-566.
7. Ellis WJ, Brawer MK. Repeat prostate biopsy: who needs it? *J Urol* 1996; 153: 1496.
8. Flanigan RC, Catalona WJ, Richie JP et al. Accuracy of digital rectal examination and transrectal ultrasonography in localizing prostate cancer. *J Urol* 1994; 152: 1506-1509.
9. Roehrborn CG, Pickens GJ, Sanders JS. Diagnostic yield of repeated transrectal ultrasound-guided biopsies stratified by histopathologic diagnoses and prostate specific antigen levels. *Urology* 1996; 57: 347-352.
10. Onik G, Barzell W. Transperineal 3D mapping biopsy of the prostate: An essential tool in selecting patients for focal prostate cancer therapy. *Urol Oncol Sem Orig Investig* 2008; 26: 506-510.
11. Webb JAW, Shanmuganathan K, McLean A. Complications of Ultrasound-guided Transperineal Prostate Biopsy. A Prospective Study. *Brit J Urol* 1993; 72: 775-777.
12. Rodriguez LV, Terris MK. Risk and complications of transrectal ultrasound guided prostate needle biopsy: a prospective study and review of the literature. *J Urol* 1998; 160: 2115-2120.
13. Selby BP, Sakas G, Walter S et al. Detection of pose changes for spatial objects from projective images. *Photogrammetric Image Analysis Conference* 2007; 36: 105-110.
14. Hadaschik BA, Kuru TH, Tulea C et al. A novel stereotactic prostate biopsy system integrating preinterventional MRI and live US fusion. *J Urol*; accepted for publication.