Enhancing the Role of Ultrasound with Contrast Agents

Editor
R. Lencioni

Springer

EDITOR
Prof. Dr. Riccardo Lencioni
Division of Diagnostic and Interventional Radiology
Department of Oncology, Transplants
and Advanced Technologies in Medicine
University of Pisa
Pisa, Italy

CD-ROM EDITED BY
Prof. Dr. Riccardo Lencioni
Dr. Clotilde Della Pina
Division of Diagnostic and Interventional Radiology
Department of Oncology, Transplants
and Advanced Technologies in Medicine
University of Pisa
Pisa, Italy

Library of Congress Control Number: 2006921996

ISBN 10 88-470-0475- 6 Springer Milan Berlin Heidelberg New York
ISBN 13 978-88-470-0475- 7 Springer Milan Berlin Heidelberg New York

Springer is a part of Springer Science+Business Media
springer.com

Printed in Italy

This textbook was funded in part by an educational grant from Bracco. Bracco, however, exercises no editorial comment, review, or any other type of control over the content of this textbook.

Cover design: Simona Colombo, Milan, Italy
Typesetting: Graphostudio, Milan, Italy
Printing and binding: Arti Grafiche Nidasio, Assago (Milan), Italy

II.8

European Guidelines in Liver Contrast Ultrasound

Riccardo Lencioni, Clotilde Della Pina, Dania Cioni, Laura Crocetti and Carlo Bartolozzi

Introduction

Detection and characterization of focal liver lesions is an important and challenging issue. Hepatocellular carcinoma (HCC) is the fifth most common cancer [1]. The liver is the organ most frequently involved by metastases. In addition, benign liver lesions, such as hemangioma and focal nodular hyperplasia (FNH), have a high prevalence in the general population. Several imaging modalities and diagnostic protocols have been used in attempts to optimize detection and characterization of focal liver lesions.

Ultrasound (US) is the most commonly used liver imaging modality. Unfortunately, US has limited sensitivity for the detection of small tumor nodules. Moreover, US findings are often non-specific, as there is enough variability and overlap in the appearance of benign and malignant liver lesions to make a definite distinction problematic. Computed tomography (CT) and magnetic resonance (MR) imaging are commonly used to clarify questionable US findings and to provide a more comprehensive assessment of the liver parenchyma.

Recently, the introduction of microbubble contrast agents and the development of contrast-specific techniques have opened up new prospects in liver US [2]. Contrast-specific techniques produce images based on non-linear acoustic effects of microbubbles and display enhancement in gray-scale, maximizing contrast and spatial resolution. The goal of improving the US assessment of focal lesions was initially pursued through scanning the liver with high mechanical index techniques. With these techniques, the signal is produced by the collapse of the microbubbles. The main limitations of this destructive method is that it produces a transient display of the contrast agent. Thus, it requires intermittent scanning, and a series of sweeps have to be performed in an attempt to cover the whole liver parenchyma. The advent of second-generation agents - that have higher harmonic emission capabilities - has been instrumental in improving the ease and the reproducibility of the examination [3]. In fact, a lower, non-destructive mechanical index can be used, thus enabling continuous real-time imaging. Over the past few years, several reports have shown that real-time contrast-enhanced US can substantially improve detection and characterization of focal liver lesions with respect to baseline studies [4].

With the publication of the guidelines for the use of contrast agents in liver US by the European Federation of Societies for Ultrasound in Medicine and Biology (EFSUMB), contrast-enhanced US has entered into clinical practice [4]. The guidelines define the indications and recommendations for the use of contrast agents in focal liver lesion detection, characterization, and post-treatment follow-up. In this paper, we discuss the impact of EFSUMB guidelines on diagnostic protocols currently adopted in liver imaging with regard to four clinical scenarios: (1) characterization of focal liver lesions of incidental detection; (2) diagnosis of HCC in patients with cirrhosis; (3) detection of hepatic metastases in oncology patients; and (4) guidance and assessment of the outcome of percutaneous tumor ablation procedures.

Characterization of Incidental Focal Liver Lesions

Characterization of focal lesions of incidental detection is one of the most common and sometimes troublesome issues in liver imaging.

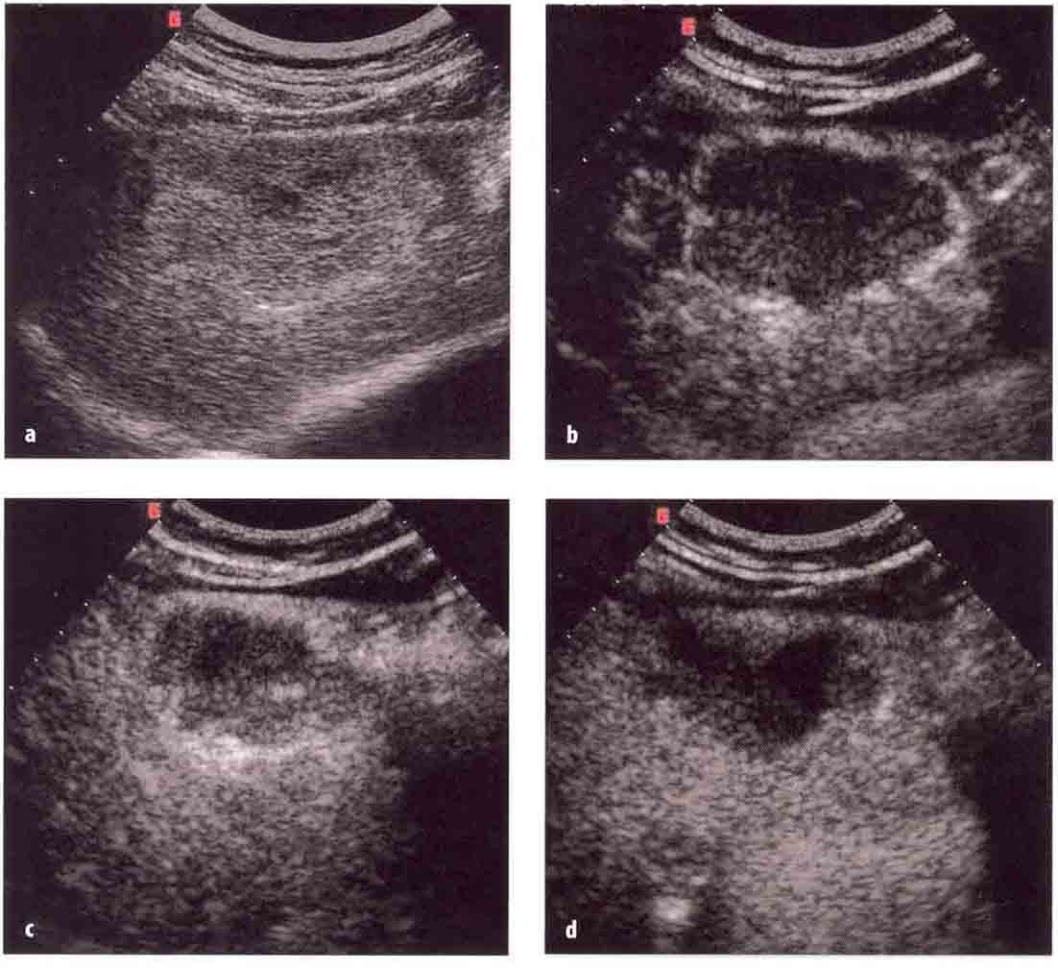

Fig. 1a-h. *Hemangioma.* At baseline US, the lesion has atypical features and appears as an iso-hypoechoic nodule (**a**). At contrast-enhanced US, the lesion shows peripheral nodular enhancement in the arterial phase (**b**) with centripetal filling in the portal-venous and delayed phases (**c**, **d**). The enhancement pattern resembles that observed at multidetector CT (**e**, baseline; **f**, arterial phase; **g**, portal-venous phase; **h**, delayed phase)

Unsuspected lesions, in fact, are frequently detected in patients who have neither chronic liver disease nor history of malignancy during an US examination of the abdomen. While a confident diagnosis is usually made on the basis of US findings in cases of simple cysts and hemangiomas with typical hyperechoic appearances, lesions with non-specific US features require further investigation [5]. The patient is typically referred for contrast-enhanced CT or contrast-enhanced MR imaging of the liver.

EFSUMB guidelines recommend the use of contrast agents to diagnose benign focal lesions not characterized at baseline study. This statement is based on the ability of contrast US to allow analysis of lesion vascularity. In fact, lesions that most frequently cause incidental findings – such as hemangioma and focal nodular hyperplasia – typically show contrast-enhanced US patterns that closely resemble those at contrast-enhanced CT or contrast-enhanced MR imaging. Most liver hemangiomas

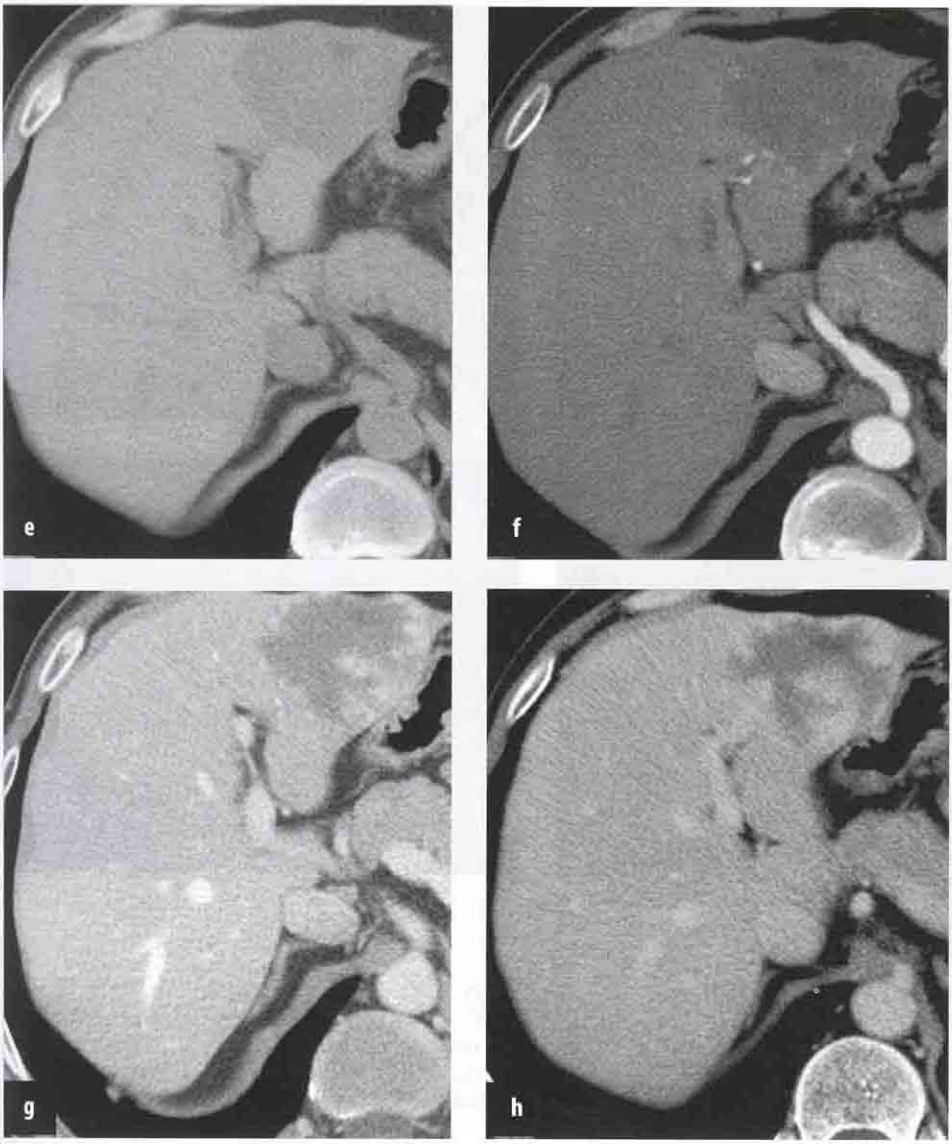

show peripheral nodular enhancement during the early phase, with progressive centripetal fill-in, leading to lesion hyperechogenicity in the late phase (Fig. 1). In two recent series, this characteristic features have been shown in 78-93% of hemangiomas [6, 7]. Focal nodular hyperplasia shows central vascular supply with centrifugal filling in the early arterial phase, followed by homogeneous enhancement in the late arterial phase. In the portal phase the lesion remains hyperechoic relative to normal liver tissue, and becomes isoechoic in the late phase (Fig. 2). This pattern has been observed in 85-100% of focal nodular hyperplasias [6, 8]. Therefore, it appears that in most liver lesions incidentally discovered at the baseline US study, detection of typical enhancement patterns after contrast injection may enable a quick and confident diagnosis, possibly avoiding the need for more complex and expensive investigations.

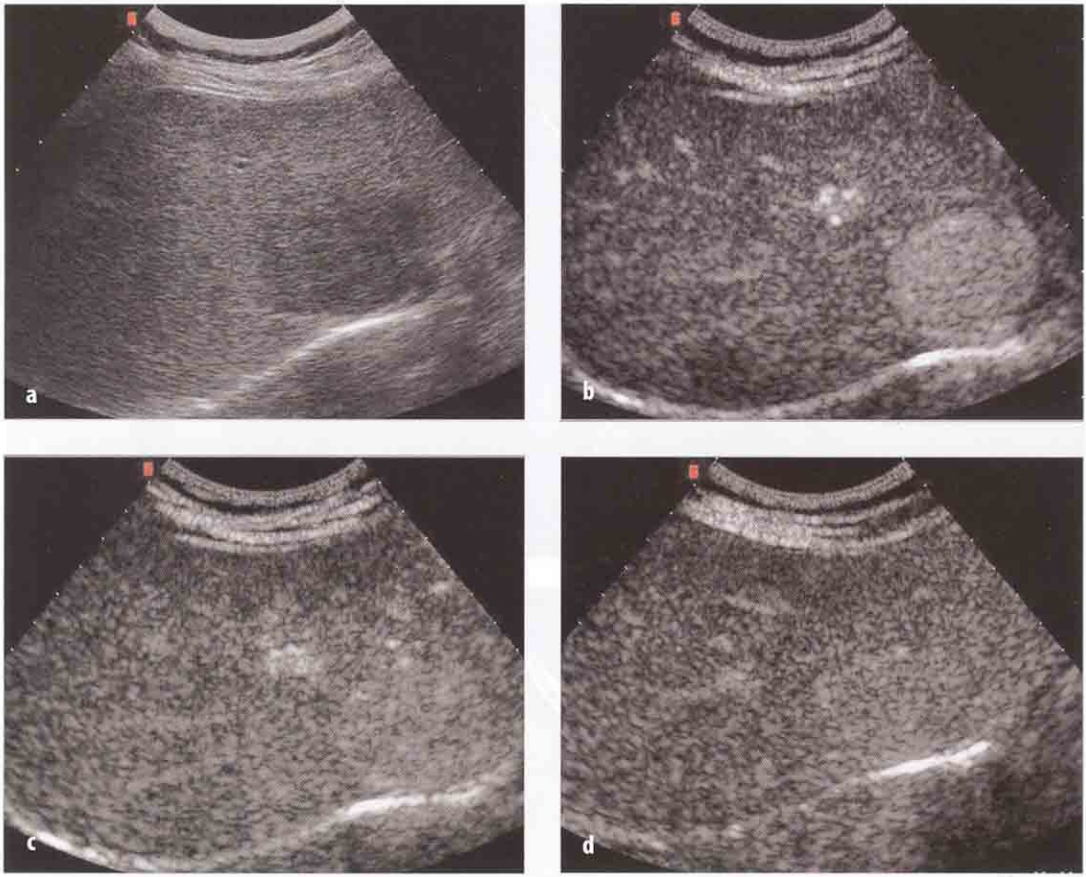

Diagnosis of Hepatocellular Carcinoma in Cirrhosis

The second clinical scenario is represented by patients with hepatic cirrhosis. In view of the high risk of developing HCC, these patients are carefully followed with US examinations repeated at six month intervals [9]. While the detection of a focal lesion in cirrhosis should always raise the suspicion of HCC, it is well established that the pathologic changes inherent to cirrhosis may simulate HCC in a variety of ways, especially because non-malignant hepatocellular lesions, such as regenerative and dysplastic nodules, may be indistinguishable from a small tumor. One of the key pathologic factors for differential diagnosis that is reflected in imaging appearances is the vascular supply to the nodule. Through the progression from regenerative nodule to dysplastic nodule to frank HCC, one sees loss of visualization of portal tracts and development of new arterial vessels, termed non-triadal arteries, which become the dominant blood supply in overt HCC. It is this neovascularity that allows HCC to be diagnosed with contrast-enhanced CT or dynamic MR imaging [10].

According to EFSUMB guidelines, a contrast-enhanced US study is recommended to characterize any lesion or suspect lesion detected at baseline US in the setting of liver cirrhosis [4]. Owing to the ability to display contrast-enhancement in real-time, contrast US appears to be a tool to show arterial neoangiogenesis associated with a malignant change, and, therefore, to help establish the diagnosis of HCC [11, 12]. HCC typically shows strong intratumoral enhancement in the arterial phase (i.e., within 25-35 seconds of the start of contrast injection) followed by rapid wash-out with isoechoic or hypoechoic appearance in the portal venous and delayed phases (Fig. 3). In contrast, large regenerative nodules and dysplastic nodules usually do not show any early contrast uptake, and resemble the enhancement pattern of liver parenchyma. Selective arterial enhancement at contrast US has been observed in 91-96% of HCC lesions, confirming

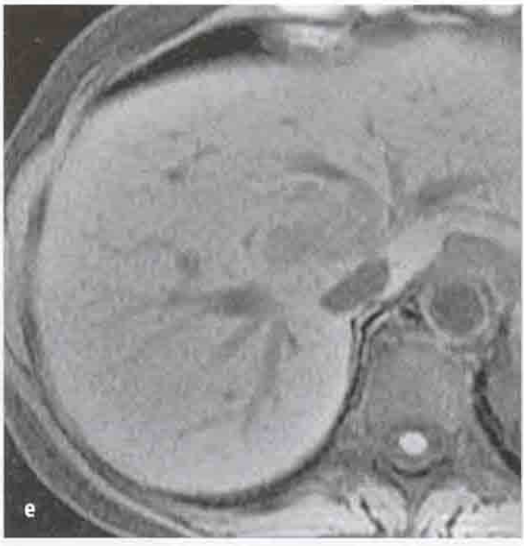

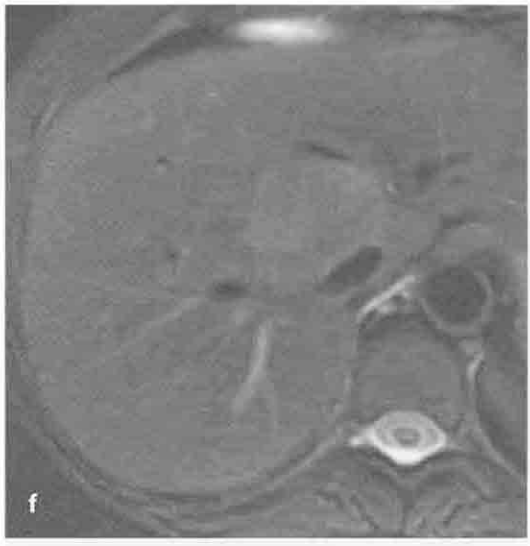

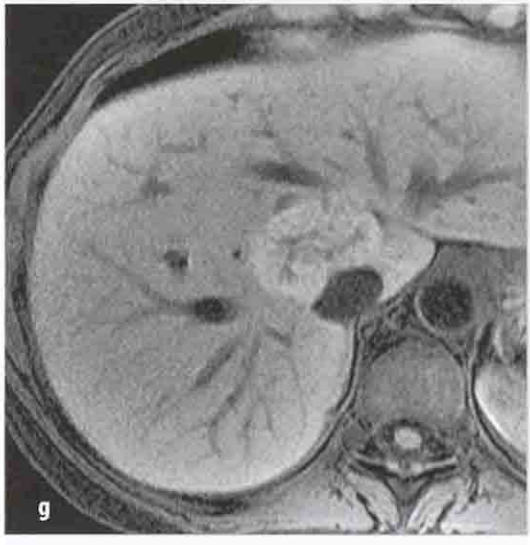

Fig. 2a-g. *Focal nodular hyperplasia.* Baseline US shows a hypoechoic lesion on segment VIII (**a**). At contrast-enhanced US the lesion shows homogeneous enhancement in the arterial phase (**b**) with isoechoic appearance in the portal and delayed phases (**c**, **d**). At MR imaging, focal nodular hyperplasia appears slightly hypointense on the T1-weighted image (**e**), slightly hyperintense on the T2-weighted image (**f**), and hyperintense on the T1-weighted image acquired 1 hour after the injection of an hepatospecific contrast agent (**g**)

that contrast US may be a useful tool to show arterial neoangiogenesis of HCC [11, 12]. In a recent study, in which findings at spiral CT were assumed as the gold standard, the sensitivity of contrast US in the detection of arterial hypervascularity was 97% in lesions larger than 3 cm, 92% in lesions ranging 2-3 cm, 87% in lesions ranging 1-2 cm, and 67% in lesions smaller than 1 cm [12]. Hence, performing a contrast-enhanced study may be recommended in all lesions or suspected lesions - 1 cm or larger in diameter - detected at baseline US in patients with cirrhosis or chronic hepatitis undergoing surveillance programs.

The use of contrast US as a reliable alternative to CT or MR imaging for characterizing nodular lesions detected by US surveillance has been recently endorsed by the American Association for the Study of Liver Diseases [13]. The diagnostic protocol is structured according to the actual risk of malignancy and the possibility of achieving a reliable diagnosis. Since the prevalence of HCC among US-detected nodules is strongly related to the size of the lesion, the work-up depends on the size of the lesion (Fig. 4) [13]. Lesions smaller than 1 cm in diameter have a low likelihood of being HCC, and only need to be followed-up in order to detect growth suggestive of malignant transformation. When the nodule exceeds 1 cm in size, the lesion is more likely to

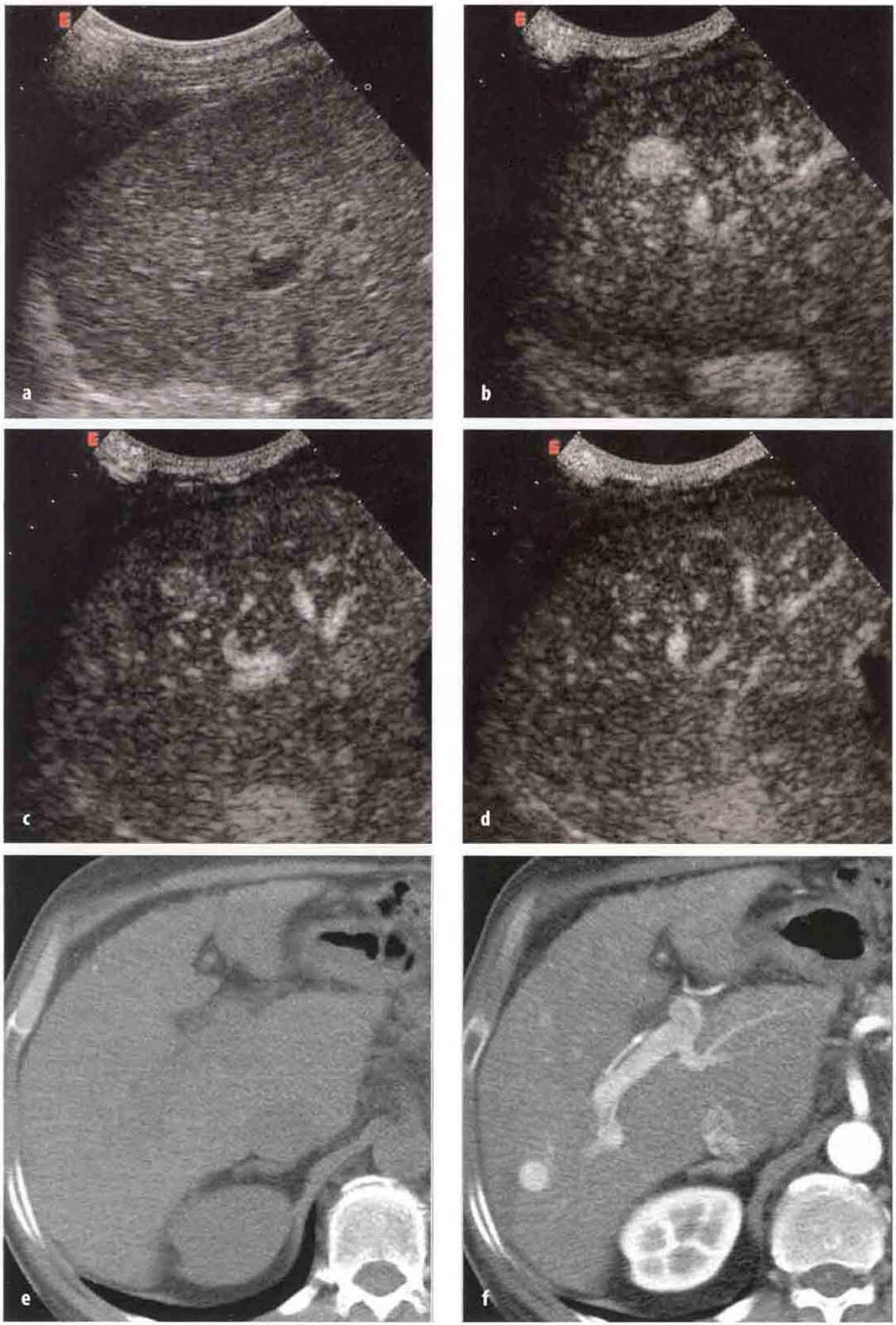
a
b
c
d
e
f

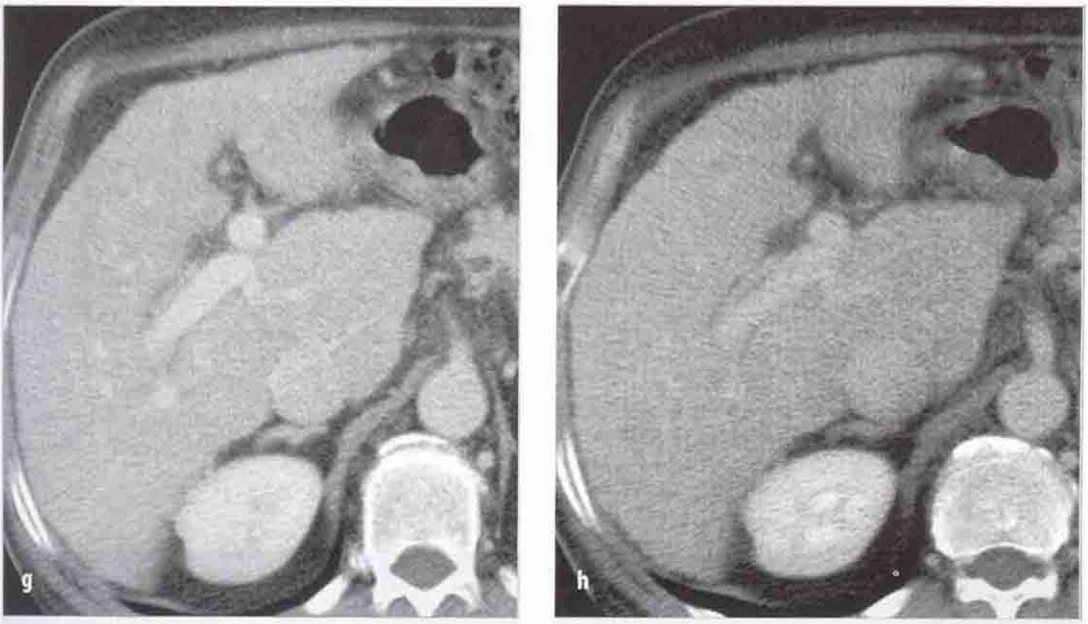

Fig. 3a-h. *Hepatocellular carcinoma.* At baseline US examination the lesion appears as an iso-hypoechoic nodule (**a**). At contrast-enhanced US, the lesion shows early enhancement in the arterial phase (**b**) with rapid wash-out in the portal-venous and delayed phases (**c**, **d**). At multidetector CT (**e**, baseline; **f**, arterial phase; **g**, portal-venous phase; **h**, delayed phase) the same enhancement pattern is *observed*

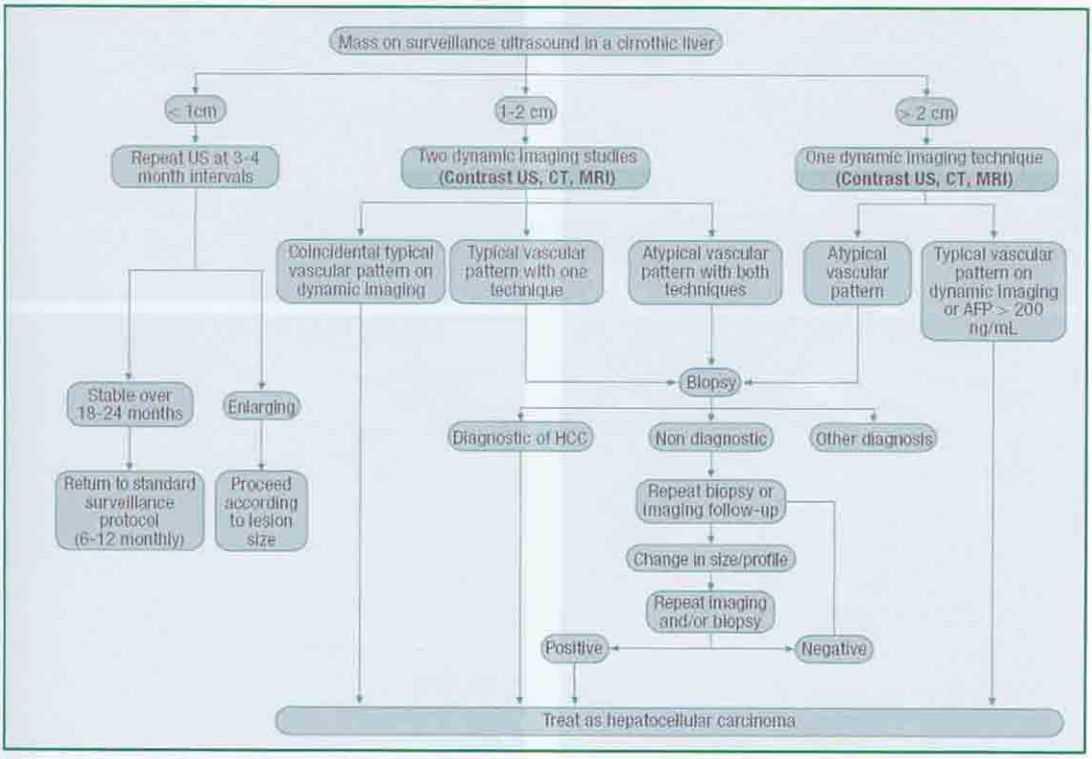

Fig. 4. Suggested algorithm for investigation of a nodule found on US during screening or surveillance. The typical vascular pattern means that the lesion is hypervascular in the arterial phase, and washes out in the portal/venous phase (Modified from [13])

be HCC and diagnostic confirmation should be pursued. It is accepted that the diagnosis of HCC in cirrhosis can be made without biopsy in a nodule larger than 1 cm that shows characteristic vascular features of HCC – i.e., arterial hypervascularization with wash-out in the portal venous or delayed phase - even in patients with normal alpha-fetoprotein values. For lesions ranging 1-2 cm, current guidelines require typical imaging findings to be confirmed by two coincident dynamic imaging modalities – out of contrast-enhanced US, contrast-enhanced multidetector CT, and contrast-enhanced MRI – to allow a non-invasive diagnosis [13]. If the imaging findings are not characteristic or the vascular profile is not coincidental among techniques, biopsy is recommended [13].

Detection of Hepatic Metastases in Oncology Patients

Metastatic disease involving the liver is one of the most common issues in oncology. CT and positron emission tomography (PET) are used in oncology protocols to provide objective documentation of the extent of the liver tumor burden and to effectively assess extrahepatic disease. Nevertheless, US is widely used in post-treatment follow-up to monitor tumor response and to detect the emergence of new hepatic metastatic lesions. One of the major points addressed by the EFSUMB document is the use of contrast agents in this patient population. In fact, the use of contrast agents is recommended

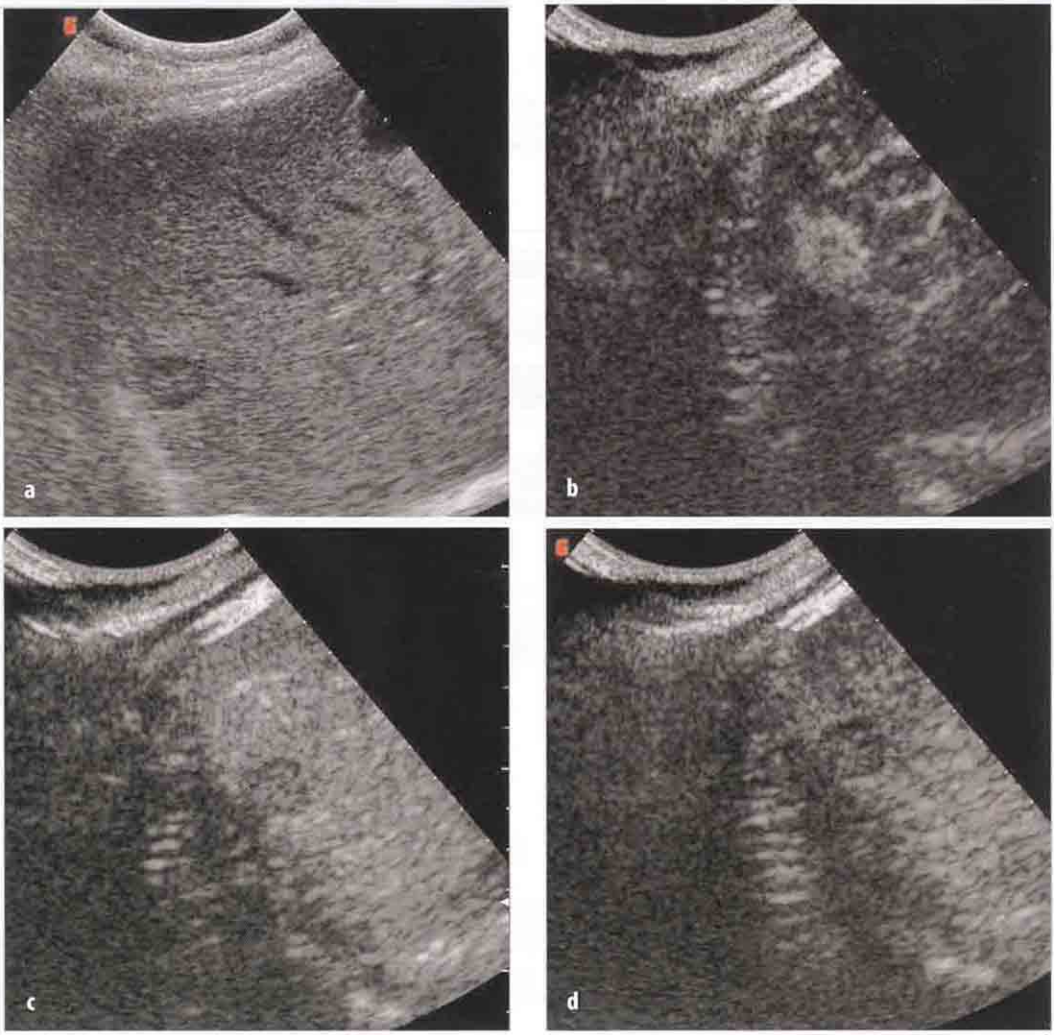

→

not only to clarify a questionable lesion detected at baseline examination. Performing a contrast-enhanced ultrasound study is recommended in every oncology patient referred for liver ultrasound, unless a clear-cut disseminated disease is detected at the baseline study. This means that all liver US examinations performed to rule out liver metastases should include a contrast-enhanced study, even if the baseline scans do not show any abnormality. This strong statement is based on a substantial increase in the ability to detect liver metastases in contrast-enhanced studies compared to baseline [14]. Even small metastases stand out as markedly hypoechoic lesions against the enhanced liver parenchyma throughout the portal venous and delayed phases (Fig. 5). The earlier the detection of liver metastatic disease, the earlier the therapeutic intervention.

Guidance and Monitoring of Tumor Ablation Procedures

Several percutaneous techniques have been developed to treat non-surgical patients with liver malignancies. These minimally invasive procedures can achieve effective and reproducible tumor destruction with acceptable morbidity. Radio-frequency ablation is increasingly accepted as the best therapeutic choice for

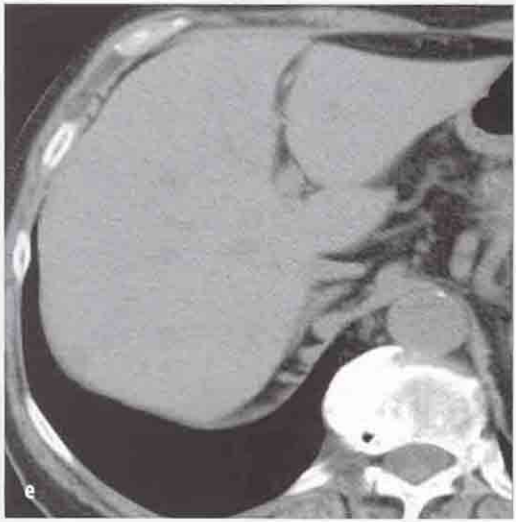

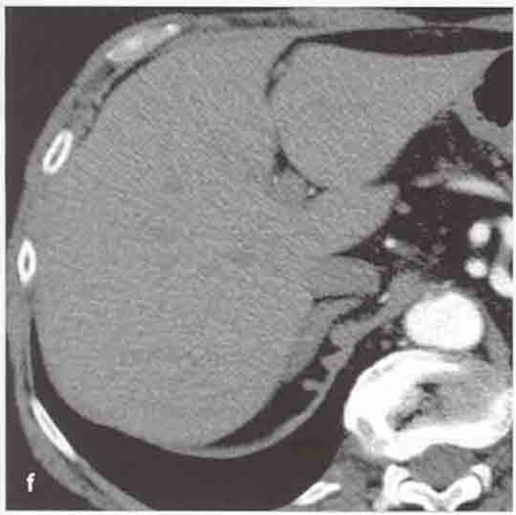

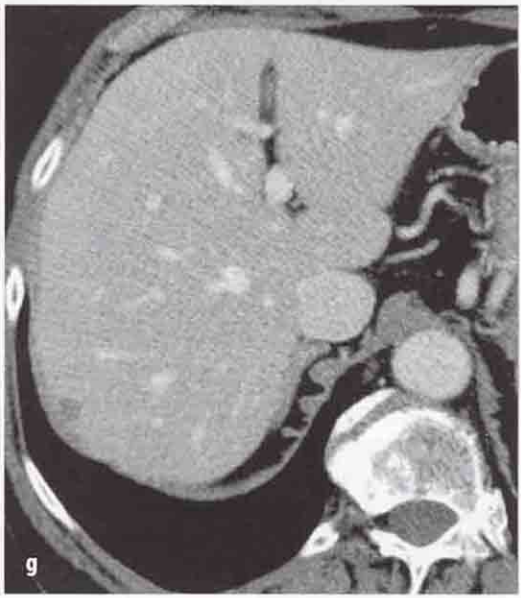

Fig. 5a-g. *Metastasis.* Baseline US examination shows a subcapsular hypoechoic nodule (**a**). At contrast-enhanced US the lesion shows rim enhancement during the arterial phase (**b**) with hypoechoic appearance in the portal-venous and delayed phases (**c**, **d**). At multidetector CT, the metastatic nodule appears hypodense in the baseline scan (**e**) as well as in the arterial (**f**) and the delayed phases (**g**)

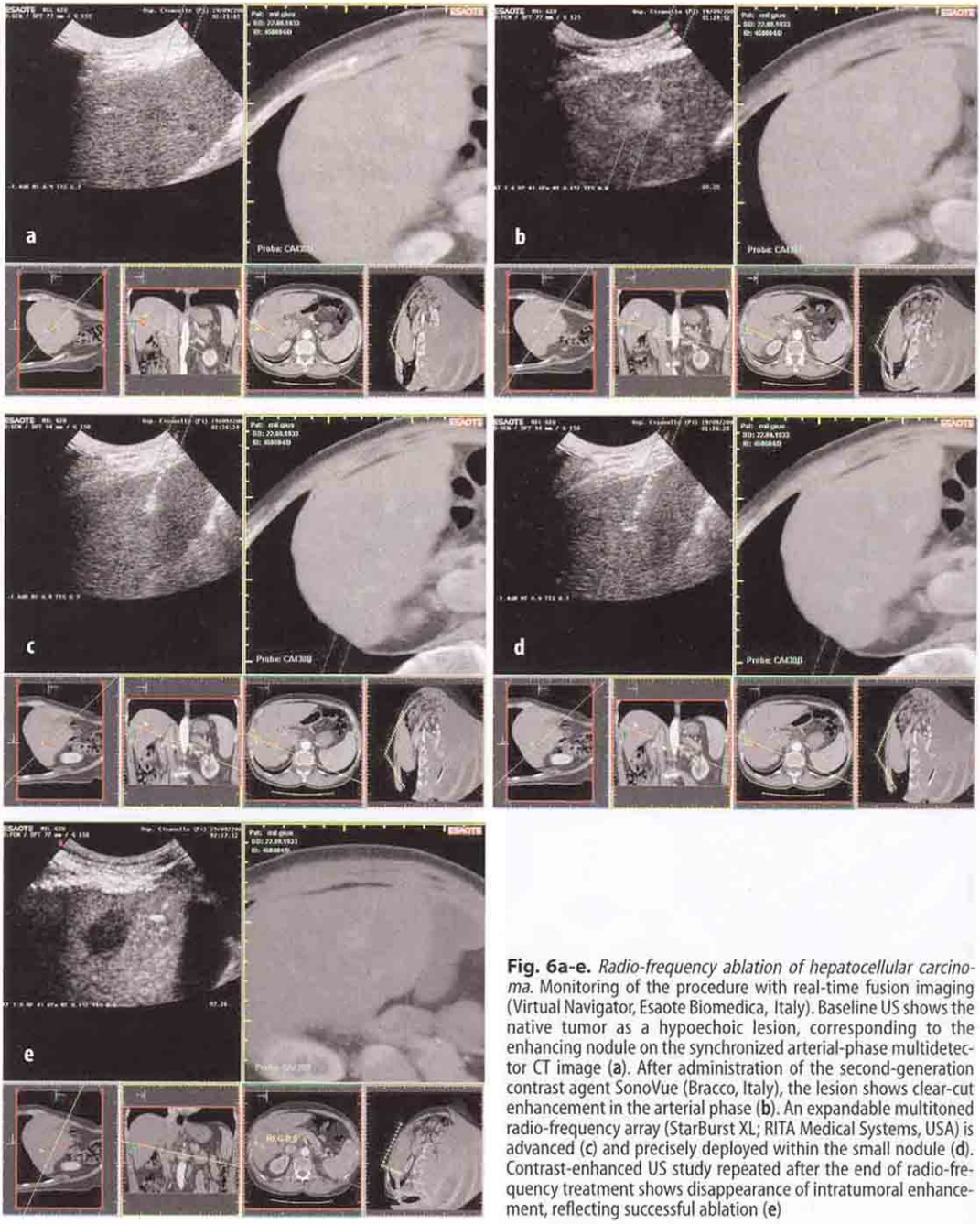

Fig. 6a-e. *Radio-frequency ablation of hepatocellular carcinoma.* Monitoring of the procedure with real-time fusion imaging (Virtual Navigator, Esaote Biomedica, Italy). Baseline US shows the native tumor as a hypoechoic lesion, corresponding to the enhancing nodule on the synchronized arterial-phase multidetector CT image (**a**). After administration of the second-generation contrast agent SonoVue (Bracco, Italy), the lesion shows clear-cut enhancement in the arterial phase (**b**). An expandable multitoned radio-frequency array (StarBurst XL; RITA Medical Systems, USA) is advanced (**c**) and precisely deployed within the small nodule (**d**). Contrast-enhanced US study repeated after the end of radio-frequency treatment shows disappearance of intratumoral enhancement, reflecting successful ablation (**e**)

patients with early-stage HCC when resection or transplantation are precluded and has also become a viable treatment method for patients with limited hepatic metastatic disease from colorectal cancer who are not eligible for surgical resection [15, 16].

When US is used as the imaging modality for guiding ablations, the addition of contrast agent can provide additional important information throughout all the procedural steps: it improves delineation and conspicuity of lesions poorly visualized on baseline scans, facilitating target-

ing; it allows the immediate assessment of the outcome of treatment by showing the disappearance of any previously visualized intralesional enhancement (Fig. 6); and it may be useful in the follow-up protocols for early detection of tumor recurrence [17].

Conclusions

Despite the improvement in detection and characterization of focal liver lesions that can be achieved using contrast-enhanced US, several issues are still open. First, contrast US will hardly replace CT or MR imaging for preoperative assessment of patients with liver tumors, as these techniques still offer a more comprehensive assessment of the liver parenchyma, which is mandatory to properly plan any kind of surgical or interventional procedure. Second, the daily schedule of each US laboratory doing liver examinations will have to be reformulated, and many US laboratories will have to update their equipment and to provide proper training for their doctors. Last but not least, the cost of the introduction of contrast-enhanced US into daily practice will have to be taken into account. It can be argued that cost saving associated with patients who will no longer need a CT or MR imaging of the liver after contrast-enhanced US could largely counterbalance the cost of the examination. However, an optimal use of contrast-enhanced US will require the definition of precise diagnostic flow charts for each clinical situation. Nevertheless, contrast-enhanced US has the potential to become the primary liver imaging modality for early detection and characterization of focal lesions. Early diagnosis of primary and secondary liver malignancies greatly enhances the possibility of curative surgical resection or successful percutaneous ablation, resulting in better patient care and eventually in improved patient survival.

Key Points

- Several reports have shown that real-time contrast-enhanced US substantially improves detection and characterisation of focal liver lesions with respect to baseline US.
- The European Federation of Societies for Ultrasound in Medicine and Biology (EFSUMB) has issued guidelines that define the indications and recommendations for the use of contrast agents in liver US.
- EFSUMB guidelines are producing a major impact on diagnostic protocols for all the main clinical situations: (1) characterisation of focal liver lesions of incidental detection; (2) diagnosis of hepatocellular carcinoma in patients with cirrhosis; (3) detection of hepatic metastases in oncology patients; and (4) guidance and assessment of the outcome of percutaneous tumor ablation procedures.
- The use of contrast US as a reliable alternative to CT and MR imaging in characterising nodular lesions detected by US surveillance in patients with cirrhosis as hepatocellular carcinoma has been recently endorsed by the American Association for the Study of Liver Diseases.

References

1. Llovet JM, Burroughs A, Bruix J (2003) Hepatocellular carcinoma. Lancet 362:1907-1917
2. Lencioni R, Cioni D, Bartolozzi C (2002) Tissue harmonic and contrast-specific imaging: back to gray scale in ultrasound. Eur Radiol 12:151-165
3. Lencioni R, Cioni D, Crocetti L et al (2002) Ultrasound imaging of focal liver lesions with a second-generation contrast agent. Acad Radiol 9 Suppl 2:S371-374
4. Albrecht T, Blomley M, Bolondi L et al; EFSUMB Study Group (2004) Guidelines for the use of contrast agents in ultrasound. January 2004. Ultraschall Med 25:249-256
5. Lencioni R, Cioni D, Crocetti L et al (2004) Magnetic resonance imaging of liver tumors. J Hepatol 40:162-171
6. Wen YL, Kudo M, Zheng RQ et al (2004) Characterization of hepatic tumors: value of contrast-enhanced coded phase-inversion harmonic angio. AJR Am J Roentgenol 182:1019-1026
7. Quaia E, Calliada F, Bertolotto M et al (2004) Characterization of focal liver lesions with contrast-specific US modes and a sulfur hexafluoride-filled microbubble contrast agent: diagnostic performance and confidence. Radiology 232:420-430

III.3

Abdominal Vessels

Alberto Martegani, Luca Aiani and Claudia Borghi

Introduction

Technological development of colour Doppler equipment (CD) has enabled endovascular flow phenomena to be more easily understood, but this imaging technique is still limited by some physical restrictions [1, 2].

In fact, the more haematic flow velocity is reduced, the less CD sampling is able to distinguish colour signals coming from vessel walls and surrounding tissues from those derived from corpuscular haematic components. This difficulty gives rise to an intrinsic CD artefact that remarkably affects its diagnostic efficacy, particularly in physiological or pathological 'slow flow' conditions.

In clinical practice, the less favourable haemodynamic situation occurs in 'stationary' flow conditions, such as aneurysmatic dilations, hypersevere stenoses or peri-vascular hemorrhagic collections. Neither modern technologies such as power Doppler (Energy), nor the grey-scale coding of flow phenomena (B-flow) are able to overcome these limitations [3].

Microbubbles are the corpuscular components of ultrasound contrast agents and are detected and depicted in real-time also in extremely reduced flow, if a dedicated and sufficiently sensitive ultrasound system is used [4, 5].

Low Mechanical Index (MI) techniques, such as contrast-enhanced ultrasound (CEUS) achieve this goal as they obtain a more linear contrast *media* signal owing to almost absent microbubble destruction and a more proportional ratio between bubble concentration and signal entity. In addition, through a subtraction of the signal coming from steady tissues, it strongly enhances even low concentrations of microbubbles.

For these reasons, it is easy to understand how this approach has recently found many fields of application with a real clinical interest.

Abdominal Aortic, Iliac and Visceral Aneurysmatic Dilatations

Ultrasound diagnosis of abdominal aortic aneurysms (AAA) is based on evaluation of the dimensions of the involved vessel, basically, on its transversal diameter; this information is easily obtained with the bare grey-scale image eventually integrated by CD module morpho-functional evaluations (Fig. 1).

On the other hand, the identification of a peripheral intra-aneurysmatic thrombus is sometimes difficult using B-mode and the CD module in particular, because of the extremely reduced flow velocity inside a dilated lumen; parietal thrombi are also usually variably hypoechoic.

For the same reasons, it is sometimes difficult to detect false flow chambers with the CD module, due to the dissection of endo-aneurysmatic thrombus. On the other hand, some artefactual intrathrombotic CD signals may be depicted erroneously, due to the movement of these structures (Figs. 2, 3).

CEUS permits the correct definition of thrombi profiles, thanks to a 'contrastographic' hyperechoic depiction of blood flow; ulcerations or thrombotic dissections, supplied with blood flow, are easily detectable as well, and are not dependent on blood flow velocity (Fig. 4).

Even if this morphological information is not essential for the evaluation of the seriousness of aneurysmatic disease, it may result in the diagnosis of 'instability' and sometimes be an unfavourable sign, especially in association with abdominal pain.

In the case of a rupturing abdominal aortic aneurysm, when clinical conditions permit an imaging approach, CEUS is able to rapidly diagnose the aneurysm and also any haematic retroperitoneal / para-aortic bleeding (Figs. 5, 6).

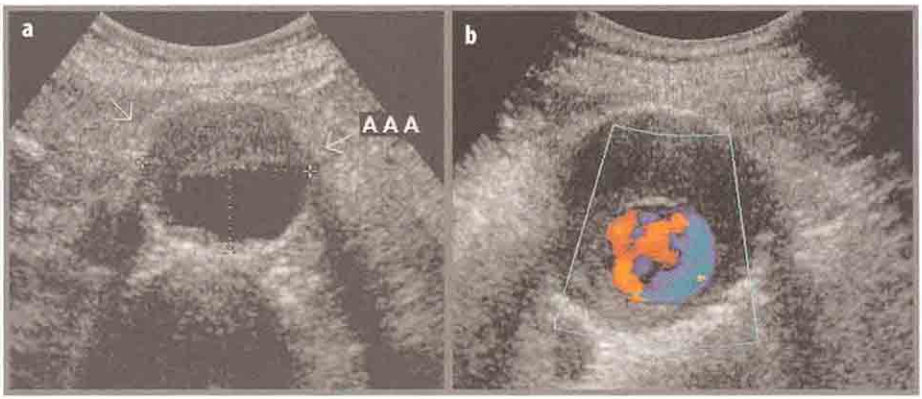

Fig. 1a, b. *Abdominal aortic aneurysms (AAA).* **a, b** Transverse US and CD scans of the aorta. An abdominal aorta aneurysm with anterior parietal thrombus is depicted (**a**). With this approach, the aneurysmatic transversal diameter is detected. **b** A peripheral thrombus, particularly thick in its anterior part, surrounds the flow chamber; CD outlines the smooth and regular thrombus surface

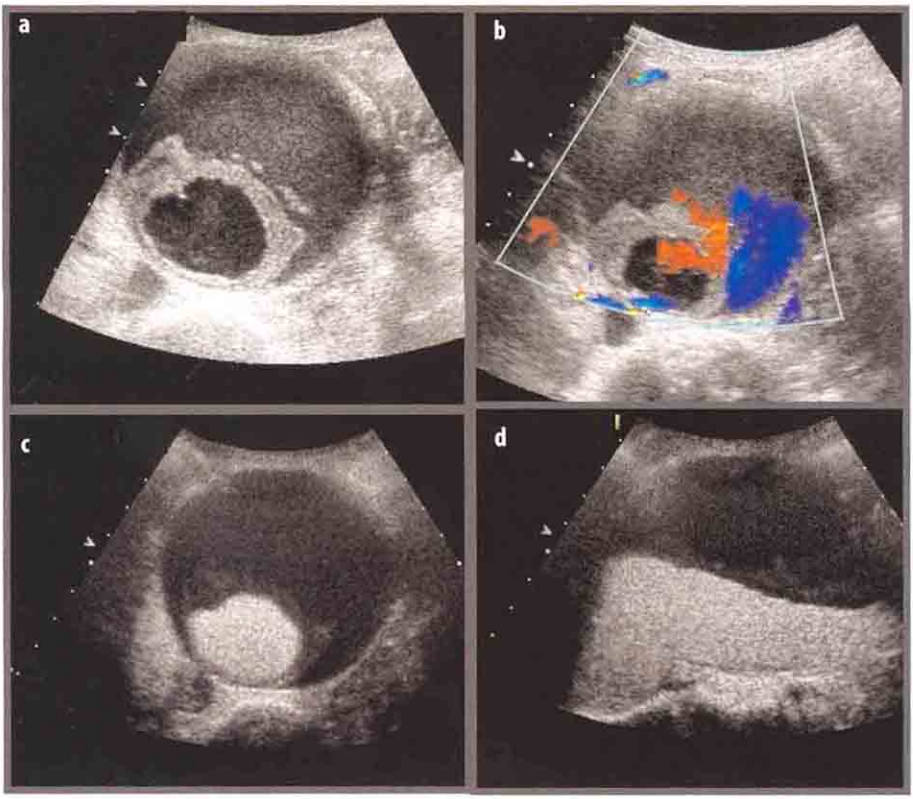

Fig. 2a-d. *Large abdominal aortic aneurysm with inhomogeneous solid and fluid thrombus.* **a, b** Transverse and longitudinal US and CD scans of the aorta. An approximately 5 cm large abdominal aortic aneurysm is presented with a thin, irregular, hyperechoic thrombus, which is 2 cm thick, delimiting the flow chamber. There is a significant, finely corpuscolar, fluid component in the left antero-lateral region, peripheral to the thin hyperechoic thrombus. The colour Doppler image of this fluid shows the presence of some sporadic colour signals (in blue). **c, d** Transverse and longitudinal CEUS scan of the aorta. The use of a contrast-specific harmonic algorithm performed at a low mechanical index nearly completely canceled out the signals derived from the stationary anatomic structures. Only minor signals from the thrombus remain (the thrombus is markedly hyperechogenic in baseline US). Approximately 20 seconds after administration of the contrast medium, hyperechogenic microbubbles appear and remain confined into the flow lumen delimited by the thin thrombus. No vascular phase shows signs of passage of the contrast medium into the fluid component of the thrombus

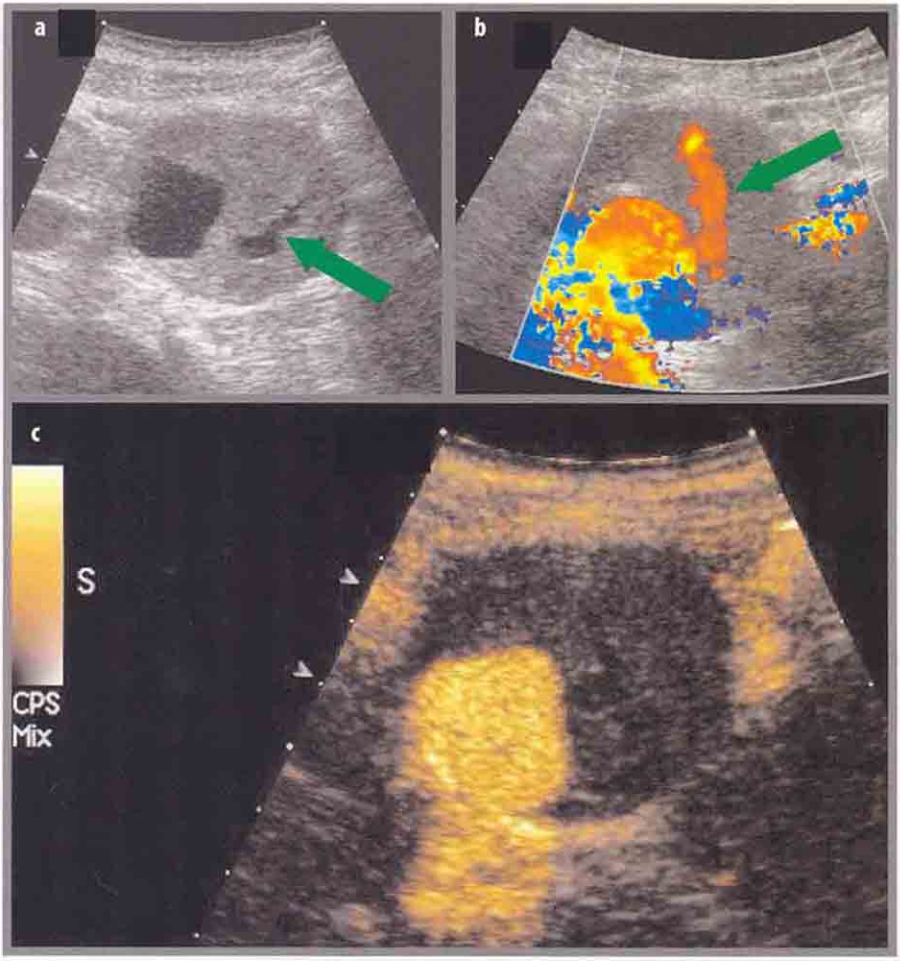

Fig. 3a-c. *AAA surrounded by a parietal layered thrombus, not supplied with blood.* **a** Transversal scan, B-mode. An AAA with homogeneous peripheral thrombus with a layered anechoic appearance (*green arrow*) is detected; the true lumen is located laterally, on the right. **b** Transversal scan, colour Doppler. A chromatic signal is detectable both inside the residual lumen and in the anechoic layer of the thrombus (in red), potentially supplying inflow (*green arrow*). **c** Transversal scan, CEUS. The aortic lumen is enhanced; inside the thrombus and its anechoic portion no signal of contrast agent is demonstrable

Use of CEUS is less common in emergency situations.

In the case of dissecting abdominal aortic aneurysms, both flow lumina are opacified and hyperechoic with CEUS; contrastosonographic kinetics help to differentiate the high flow aortic lumen from the low delivery flow lumen; the precocious enhancement permits correct identification and definition of the true lumen (Fig. 7).

In the case of extra-aortic aneurysmatic disease, involving small calibre or distal vessels (iliac, renal or splanchnic), CEUS rapidly identifies the vascular nature of these lesions; the time of transit and the intensity of contrastographic phenomena distinguishes the arterial from the venous nature (Fig. 8).

Any thrombotic endo-aneurysmatic deposition may be easily diagnosed using contrast agents, for example, in the aorta.

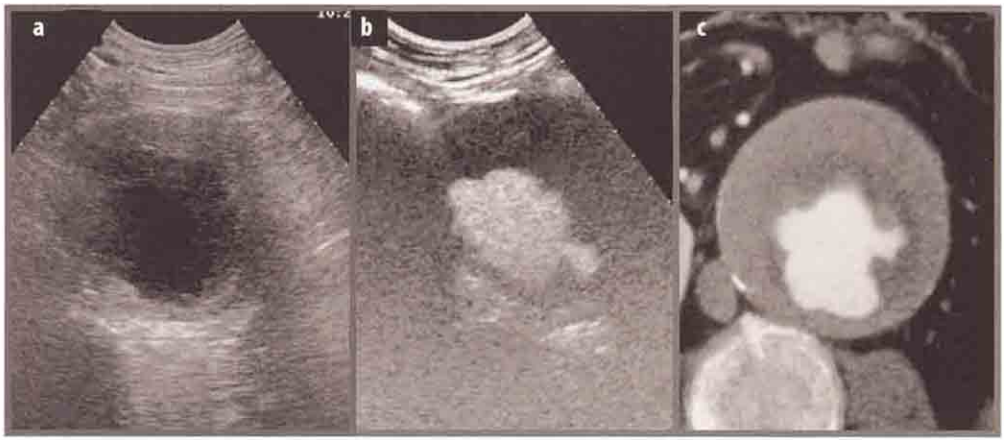

Fig. 4a-c. *Abdominal aorta aneurysm.* **a** Transversal scan, B-mode. An abdominal aortic aneurysm with an inhomogeneous, hypoechoic, peripheral thrombus is detectable; a correct evaluation of the thrombus surface and therefore of the diameter of the residual lumen is prevented, because of its morphological appearance. **b** Transversal scan, CEUS. The aortic lumen is homogeneously enhanced by contrast agent, appearing hyperechoic; the peripheral thrombus inner surface is remarkably irregular. **c** Helical angio-CT corresponding scan. Contrast agent outlines the thrombus profile; in such a situation, the residual lumen is well depicted and so is the presence of large penetrating atheromasic ulcers

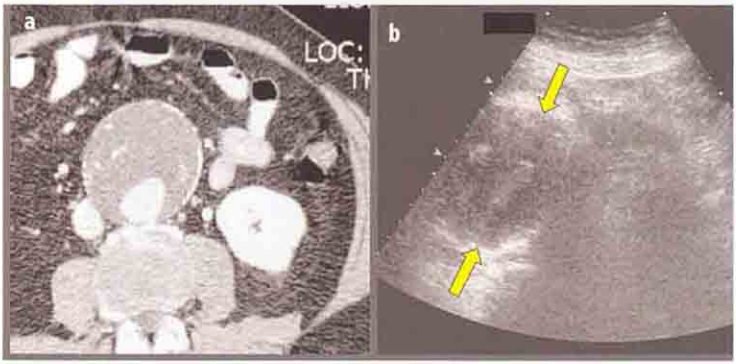

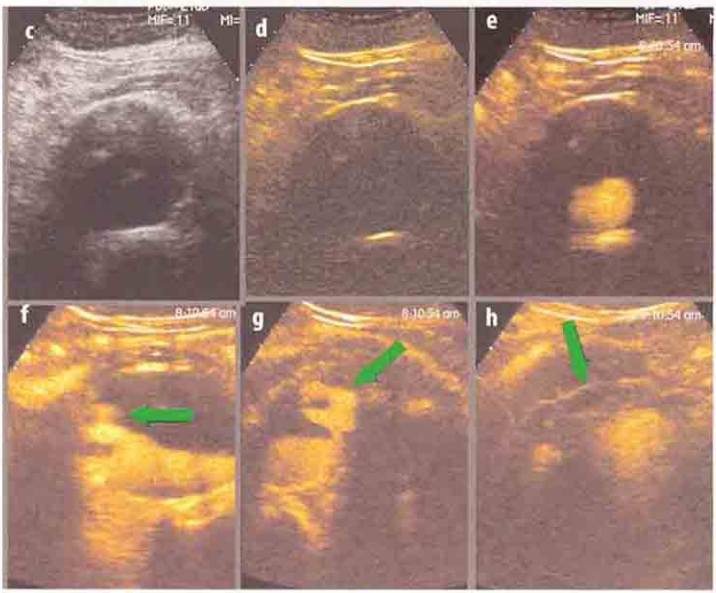

Fig. 5a-h. *Rupturing abdominal aortic aneurysm.* **a** Transversal angio-CT scan. A wide parietal thrombus delimits a small flow chamber posteriorly located in this aneurysmatic sac. **b** Transversal scan, US. Marked inhomogeneous and hypoechoic appearance of peri-aneurysmatic tissues on the left side; the aneurysm has an identical caliber to the previous scan (*yellow arrows*). **c-h** Trasversal scan, CEUS. After contrast injection, the flow lumen enhances; an irregular hyperechoic image branches off the flow lumen into an anterior thrombus (*green arrows*), corresponding to the dissection seat; a small amount of contrast agent is detectable inside the peripheral tissues, which are hypoechoic (**h**) due to the presence of a minimal blood supply in the peri-aneurysmatic haematoma

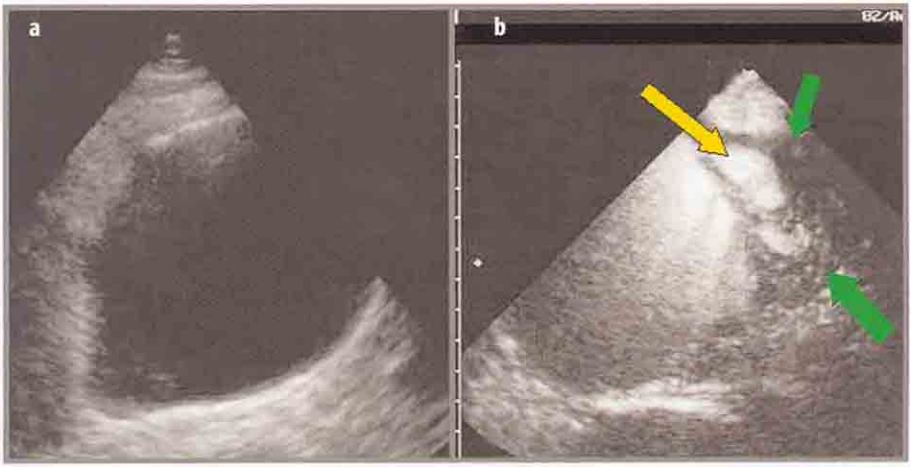

Fig. 6a, b. *Breaking AAA with para-aortic retroperitoneal haematoma supplied with blood flow.* **a** Transversal scan, B-mode. Large AAA. **b** Transversal scans, CEUS. In **b** the aortic lumen is enhanced by contrast agent; in the left retroperitoneal para-aortic space a hypoechoic semilunar mass (*green arrows*) corresponding to haematoma is depicted, in which two hyperechoic, vascularised areas are evident, corresponding to active supply (*yellow arrows*)

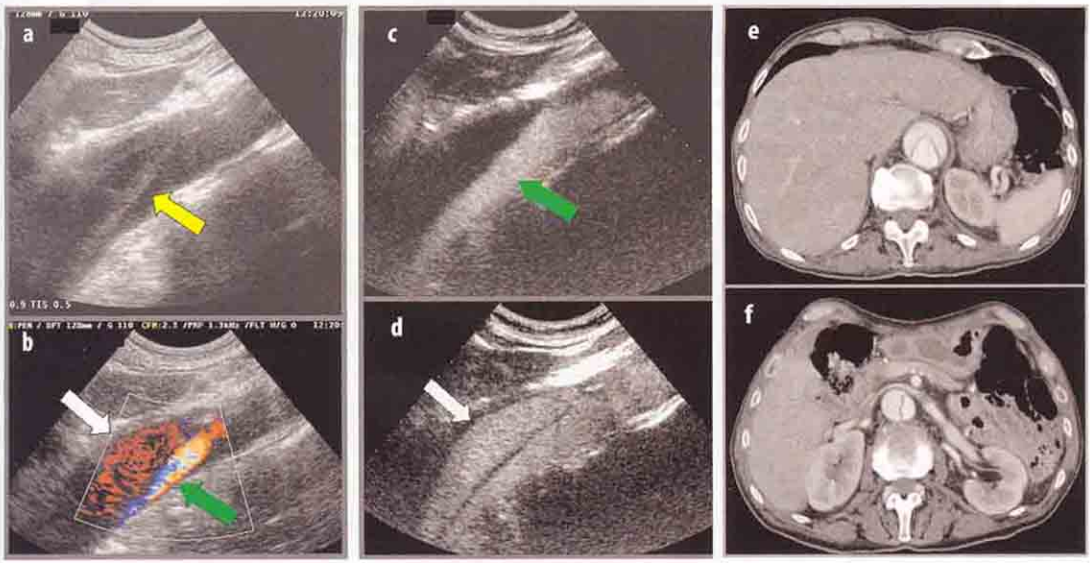

Fig. 7a-f. *Dissecting abdominal aorta aneurysm.* **a** Longitudinal scan, B-mode. The abdominal aorta is slightly enlarged; in its lumen a thin hyperechoic laminar image corresponding to dissected intima is detected (*yellow arrow*). **b** Longitudinal scan, CD. Two flow chambers with different velocity rates are depicted with CD; the posterior lumen has a high flow velocity (true lumen: *green arrow*) while anterior chamber has a slow flow velocity (false lumen: *white arrow*). **c-d** Longitudinal scan, CEUS. After contrast administration (**c**), the posterior lumen (true lumen: *green arrow*) enhances rapidly and homogeneously in early phase; in late phase (**d**) the false lumen (anterior: *white arrow*) enhances homogeneously as well. **e-f** Angio-CT, trasversal plane. The abdominal aorta is slighty enlarged; the dissected flap divides the vessel in two flow lumina

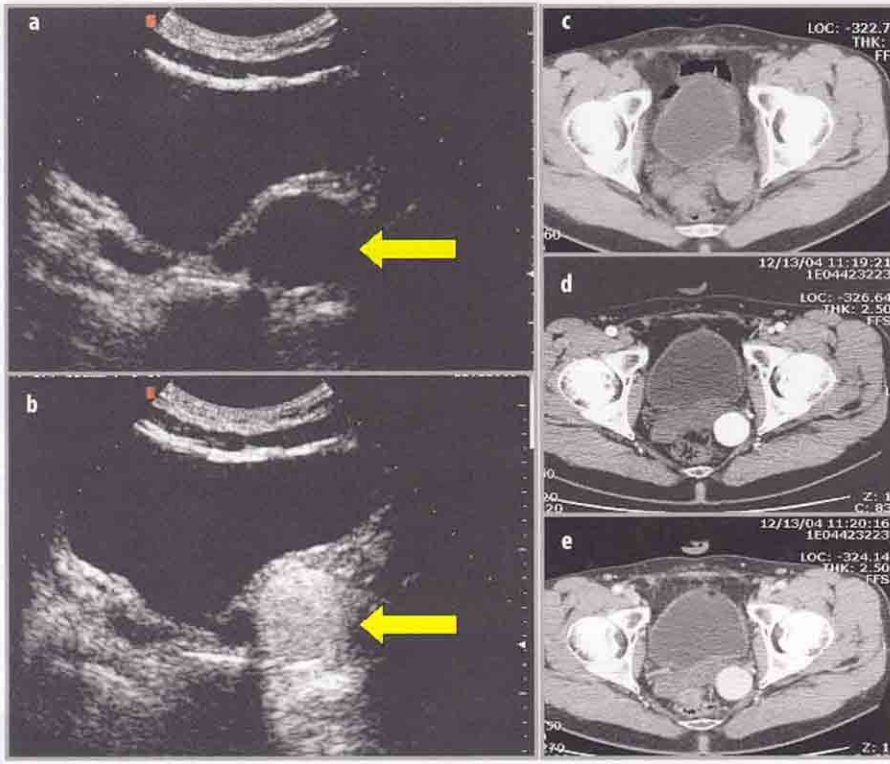

Fig. 8a-e. *Hypogastric aneurysm.* **a** Transversal scan, B-mode. A small anechoic rounded lesion (*yellow arrow*) is detected posteriorly and left laterally to the urinary bladder. **b** Transversal scans, CEUS. After contrast administration, a homogeneous enhancement inside the rounded image is already evident in arterial phase (*yellow arrow*). **c-e** Angio-CT, transversal plane. In baseline scan (**c**) the rounded image is confirmed behind the bladder; it homogeneously enhances in arterial phase (**d**) and more poorly in late vascular phases (**e**)

Follow-up of Aortic Vascular (Percutaneous or Surgical) Grafts

CEUS is a valid and consolidated diagnostic tool with computed tomography angiography (angio-CT) for the follow-up of surgically repaired aneurysms. CEUS is able to demonstrate the patency of vascular grafts and to detect any flow signal inside hypo-anechoic peri-aneurysmatic collections, helping to distinguish fluid collections such as seromas or lymphoceles from pulsating haematomas or pseudoaneurysms (Fig. 9). These last two conditions are potentially unstable, because they are supplied with blood flow, and usually require an individual therapy.

Stenoses of anastomotic seats are easily diagnosed and quantified by CD module; high flow velocities, always associated with these pathologic conditions, do not benefit from CEUS.

On the contrary, the indication of CEUS in early and late follow-up of percutaneous repair of aneurysms is extremely important; morphological and functional follow-up must exclude the presence of recanalisation of the aneurysmatic sac (endoleak) (Fig. 10) [6-9]. By CEUS, this phenomenon appears as a hyperechoic signal (corresponding to contrast agent) inside the peri-prosthetic aneurysmatic sac and may be caused by four different phenomena:

- detachment of any part of the endograft from aneurysmatic necks (type I)
- flow inversion inside a collateral vessel (type II)
- lesion of the endograft covering or rupture (type III)
- abnormal porosity of the graft covering (type IV).

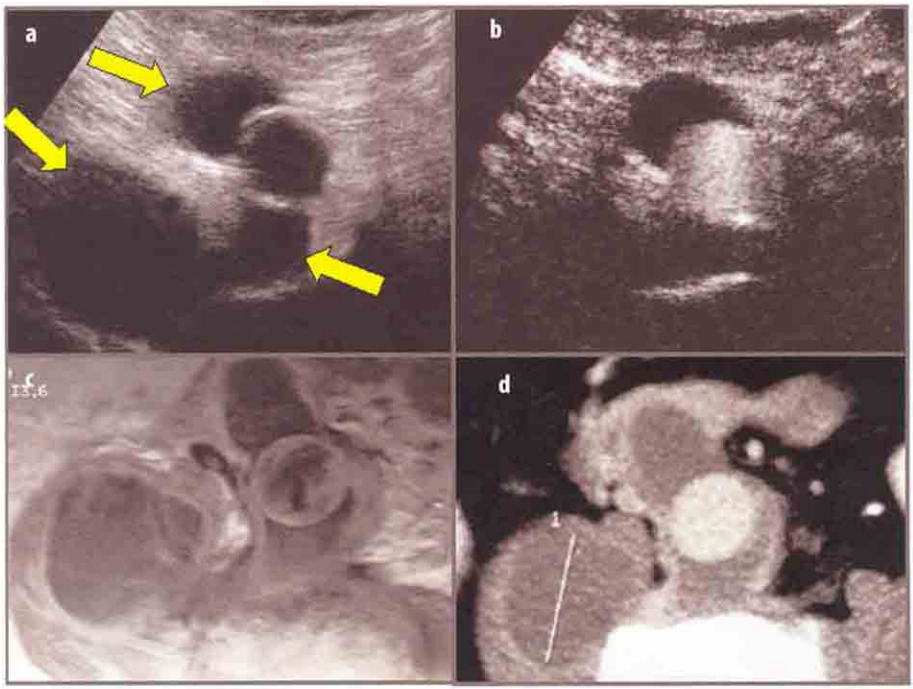

Fig. 9a-d. *Surgical aortic stentgraft with peripheral fluid collections.* **a** Transversal scan, B-mode. A linear hyperechoic rounded structure corresponding to the aortic graft is evident; anteriorly, posteriorly and in right postero-lateral position three anechoic images (*yellow arrows*) are detectable peripheral to the prosthesis, but strictly adherent to the prosthesic wall (possibly peri-prosthesic collections or anastomotic pseudo-aneurysm). **b** Transversal scan, CEUS. The prosthesic lumen is regularly enhanced by contrast agent; none of the three collections is filled with contrast, and therefore they are excluded by vascular bed. Periprosthesic collections. **c-d** Angio-RMN and angio-CT corresponding planes. No vascular supply is detected inside the three collections

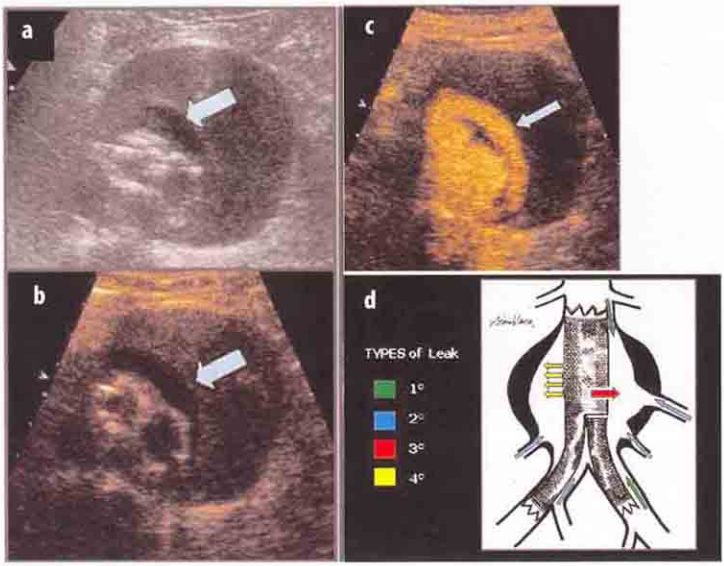

Fig. 10a-d. a B-mode transversal scan. Abdominal aortic aneurysm. Inside the sac, iliac prosthesic branches are detectable. Peripherally, a parietal thrombus with a hypo-anechoic area surrounding the prosthesis is demonstrable (*white arrow*). **b, c** Transversal CEUS scan. After contrast agent administration (**c**), a hyperechoic signal due to microbubbles appears inside the prosthesis lumen and in the fluid peri-prosthesic collection (*white arrow*), in comparison to unenhanced scan (**b**). Schematic drawing of different endoleak types (**d**)

Compared to CEUS, angio-CT, the gold standard technique, is more panoramic in its evaluation of the graft and native aorta; on the other hand, it is burdened with intrinsic limitations mainly due to the use of a potentially nephrotoxic contrast agents, which is dangerous for patients who have impaired renal function [10-13].

CEUS, in the presence of a suitable sonographic window, permits morphological and functional information to be obtained, comparable to that achieved by angio-CT (Figs. 11, 12) [14-18].

Simultaneous application of CEUS and low MI colour Doppler enables the combination of morpho-functional data with the 'direction' information necessary to comprehend the complex means of residual aneurysmatic sac supply; these two imaging modalities may identify the feeding and the efferent artery in the case of type II endoleak (Fig. 13).

CEUS also detects type IV endoleak; endograft porosity allows the filtration of contrast agent through many points of the prosthesis wall (Fig. 14).

A specific type of leakage, known as tensoleak, must be also considered; it appears as a progressive increase in the diameter of the residual aneurysmatic sac in the absence of detectable inflow phenomena. Its cause seems to be related to arterial pressure transmission from the endograft walls to the peripheral thrombus; the large aneurysmatic dimensions and the presence of a inhomogeneous thrombus mixed with fluid intrathrombotic lacunae seem to favour such pressure transmission (Fig. 15).

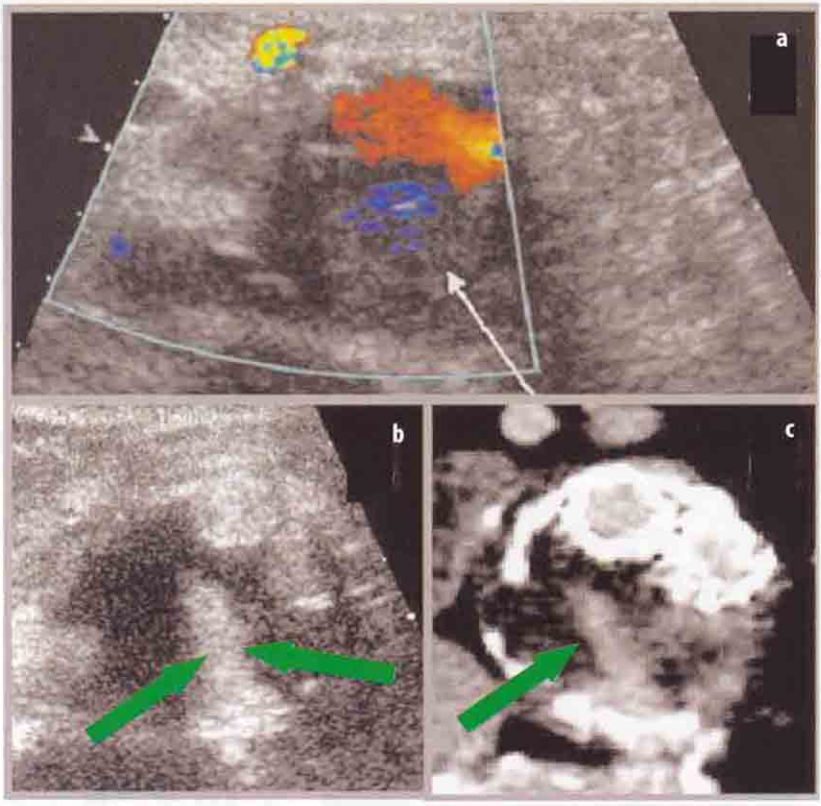

Fig. 11a-c. *Type II Endoleak.* **a** Transversal scan, colour Doppler. The aorto-iliac endovascular graft in the anterior part of the aneurysm is correctly patent; posteriorly, inside the residual thrombosed aneurysmatic sac, there is a chromatic signal (blue) (*white arrow*), which is not easily interpretable (possibly flow or artefact?). **b** Same, CEUS scans. In longitudinal (**c**) scan, the graft lumen is patent (hyperechoic); inside the residual sac, posteriorly to endoprosthesis a thin, hyperechoic, winding flow lumen (*green arrows*) is detectable (endoleak). **c** Angio-CT, trasversal plane. Aneurysmatic walls are calcified. The metallic structure of the graft iliac branches are hyperdense and so are their lumen. The leak is confirmed as a linear hyperdense image (*green arrow*), posteriorly located to the endovascular graft. There is a perfect overlapping between the flow phenomena depiction inside and outside the prosthesis of angio-CT and CEUS (**b**)

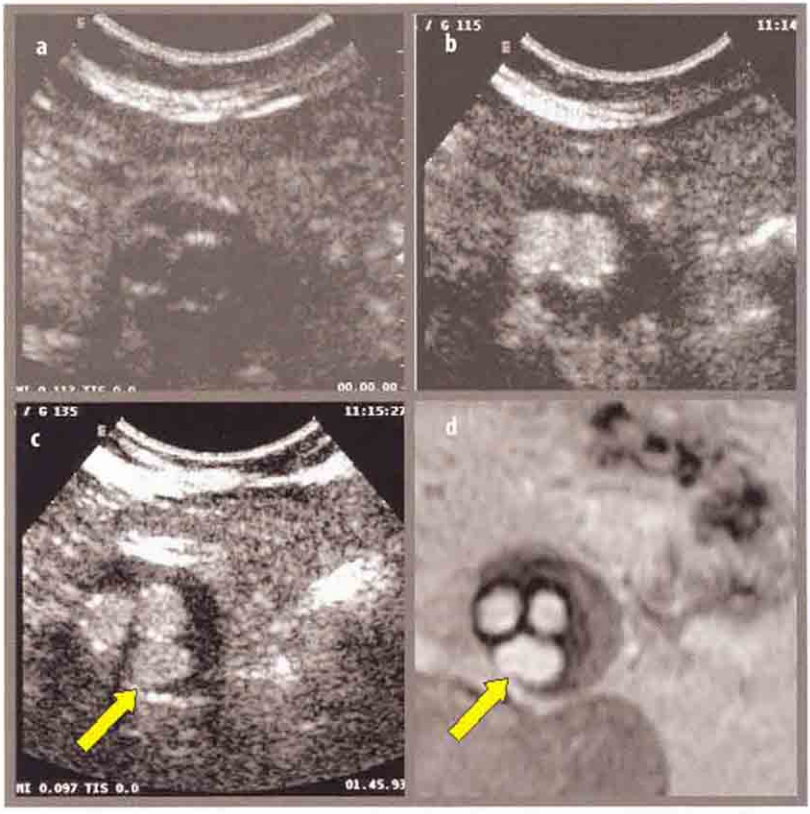

Fig. 12a-d. *Type II Endoleak.* **a-c** Transversal scan, CEUS. Before contrast administration (**a**), two linear rounded images corresponding to iliac branches of the prosthesis are evident: the graft lumen and the aneurysmatic sac are hypoechoic. After contrast injection, in early phase the iliac branches are completely filled with contrast and their lumen appears hyperechoic (**b**); in late phase, an oval-shaped hyperechoic image appears outside the prosthesis, posteriorly to the iliac branches, inside the aneurysmatic sac (*yellow arrow*) - endoleak (**c**). **d** Transversal scan, angio-NMR. Behind the patent iliac branches of the endoprosthesis, a small oval enhancement is detectable, corresponding to the endoleak

Another advantage of CEUS is linked to the opportunity of performing subsequent (also daily) follow-up examinations even at the patient's bedside; in such conditions a precise and non-invasive monitoring of the first post-therapy phases is obtained without patient discomfort.

Finally, the recently gained ability to use dedicated overlapping systems of ultrasound images in real-time, baseline and contrast-enhanced, and CT/magnetic resonance (MR) images should be mentioned. Fusion imaging is achieved using a magnetic field (generated by a transmitter) combined with a small receiver, where positioning information is acquired through second-by-second detection of the US probe.

In these conditions, the dimensions of the residual peri-prosthesic aneurysmatic sac are more precisely and easily detectable (baseline CT image), and at the same time the presence of contrast agent inside the vascular lumen, or inside the peripheral thrombus if a leakage occurs, is identifiable as well (CEUS image) (Figs. 16, 17).

This system enables the advantages of both techniques to be enhanced and their intrinsic limitations to be counterbalanced through information integration.

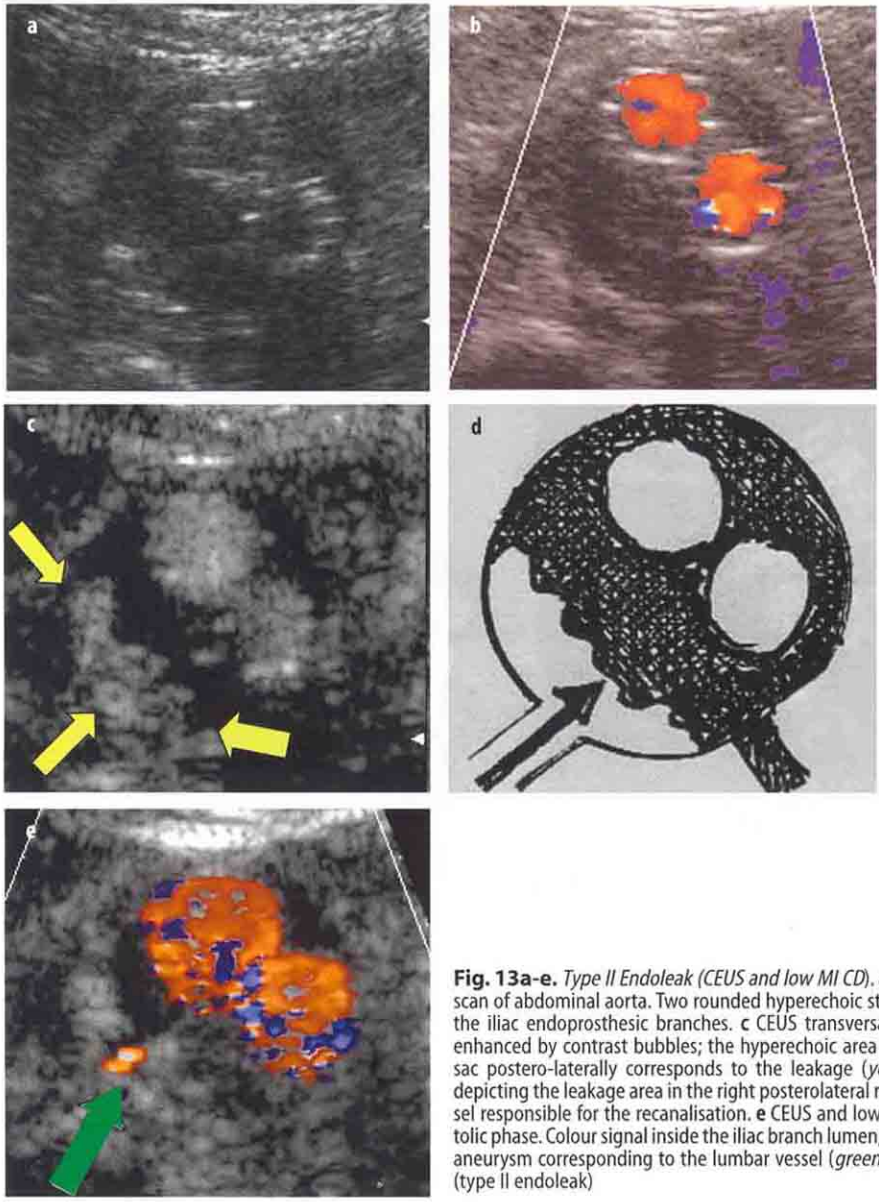

Fig. 13a-e. *Type II Endoleak (CEUS and low MI CD).* **a, b** Transversal US and CD scan of abdominal aorta. Two rounded hyperechoic structures corresponding to the iliac endoprosthesic branches. **c** CEUS transversal scan. The branches are enhanced by contrast bubbles; the hyperechoic area placed in the aneurysmal sac postero-laterally corresponds to the leakage (*yellow arrows*). **d** Drawing depicting the leakage area in the right posterolateral region and the lumbar vessel responsible for the recanalisation. **e** CEUS and low MI colour Doppler in systolic phase. Colour signal inside the iliac branch lumen; flow directed towards the aneurysm corresponding to the lumbar vessel (*green arrow*) that refills the sac (type II endoleak)

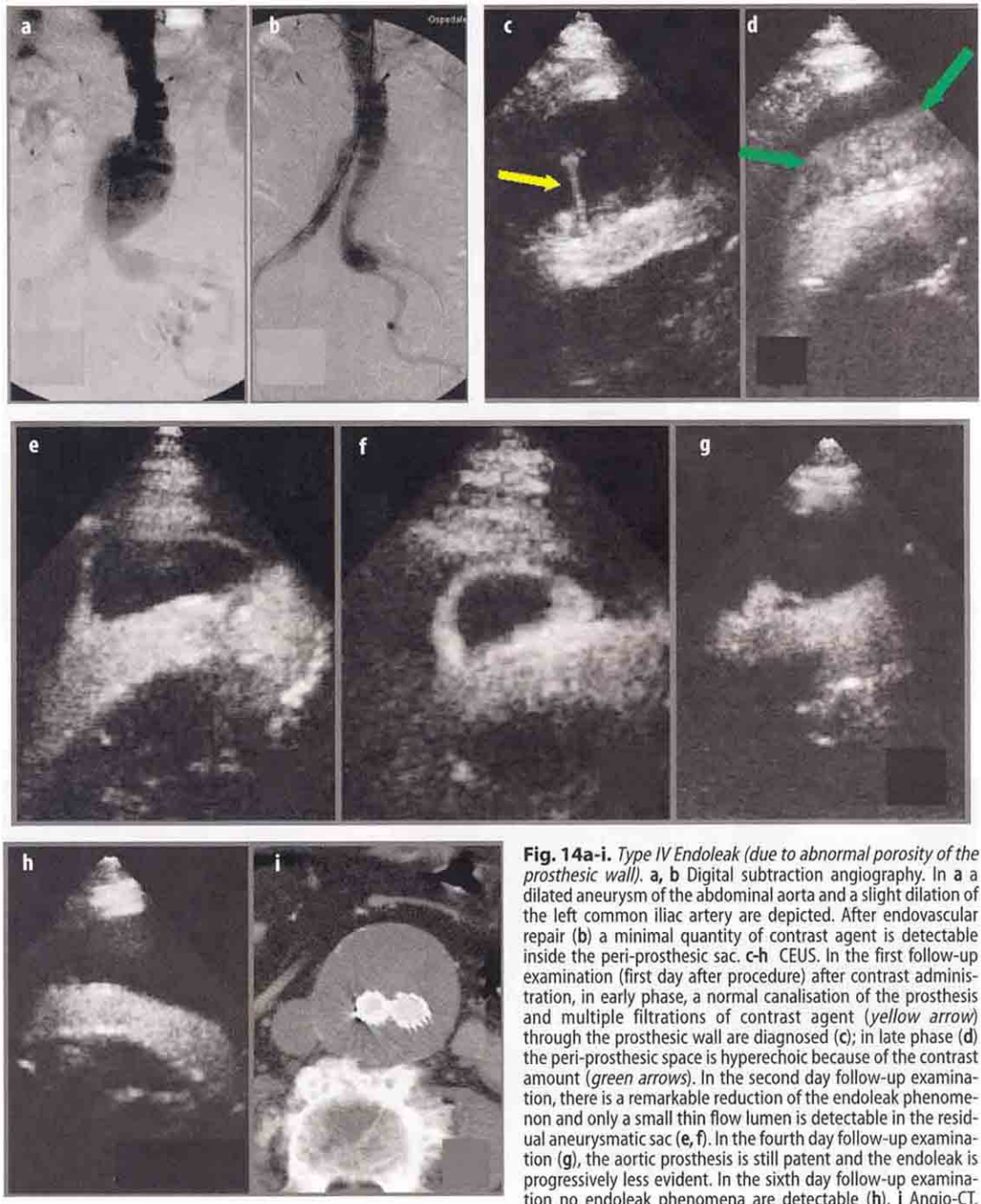

Fig. 14a-i. *Type IV Endoleak (due to abnormal porosity of the prosthesic wall).* **a, b** Digital subtraction angiography. In **a** a dilated aneurysm of the abdominal aorta and a slight dilation of the left common iliac artery are depicted. After endovascular repair (**b**) a minimal quantity of contrast agent is detectable inside the peri-prosthesic sac. **c-h** CEUS. In the first follow-up examination (first day after procedure) after contrast administration, in early phase, a normal canalisation of the prosthesis and multiple filtrations of contrast agent (*yellow arrow*) through the prosthesic wall are diagnosed (**c**); in late phase (**d**) the peri-prosthesic space is hyperechoic because of the contrast amount (*green arrows*). In the second day follow-up examination, there is a remarkable reduction of the endoleak phenomenon and only a small thin flow lumen is detectable in the residual aneurysmatic sac (**e, f**). In the fourth day follow-up examination (**g**), the aortic prosthesis is still patent and the endoleak is progressively less evident. In the sixth day follow-up examination no endoleak phenomena are detectable (**h**). **i** Angio-CT. Before discharge, the iliac branches are normally perfused; outside the graft, no contrast agent is detectable

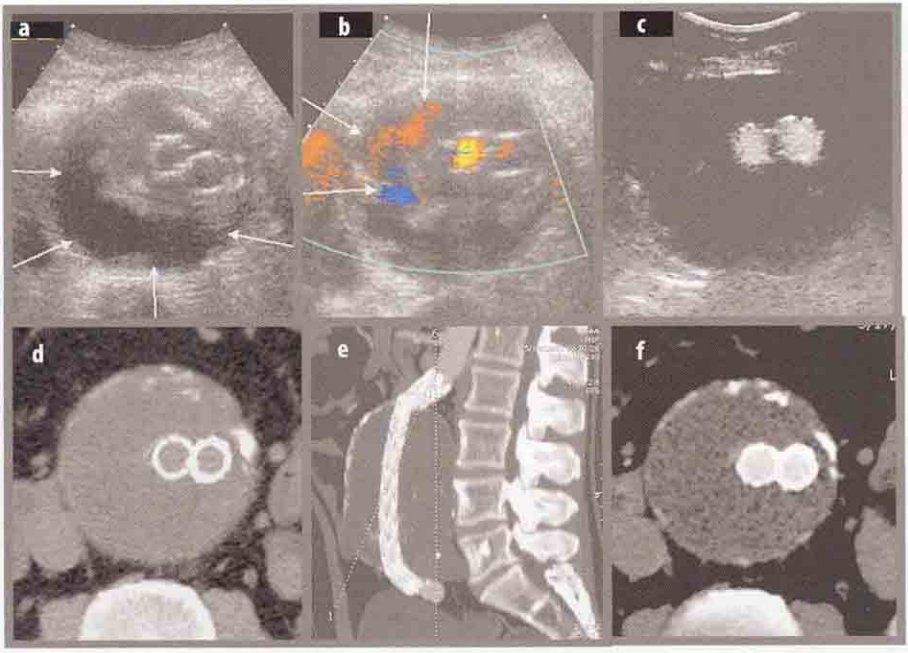

Fig. 15a-f. *Endotension.* **a** US baseline. Large sac with inhomogeneous and 'fluid' thrombus; strong hyperechoic structures correspond to endoprosthesic iliac branches. **b** Colour Doppler scan. Colour signals in iliac prosthesic branches; inside the residual thrombosed aneurysmatic sac, there is a chromatic signal (*white arrows*), not easily interpretable (possible flow or artefact?). **c** CEUS. The iliac branches enhance with contrast microbubbles; in the sac no hyperechoic sign due to contrast bubbles is detectable. **d-f** Spiral CT. Absence of contrast inside the aneurysmatic sac in early and late phase. No endoleak is evident

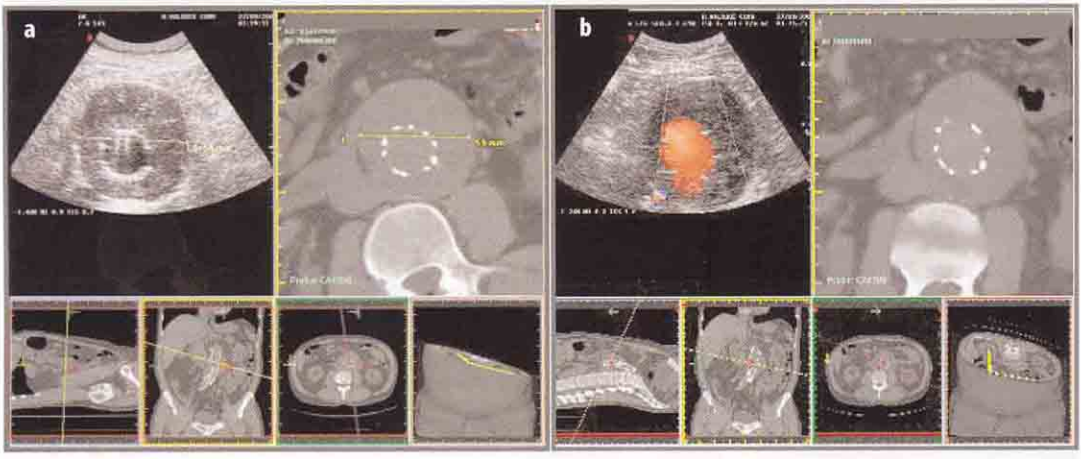

Fig. 16a, b. *Abdominal aortic aneurysm and fusion imaging US-CD/CT.* **a** Precise correlation between US transversal scan and analogous baseline CT transversal scan. **b** Correlation between CD transversal scan and analogous baseline CT transversal scan. The coupling system enables a comparison in the same screen in 'real-time' between US and/or CD images and corresponding CT scan

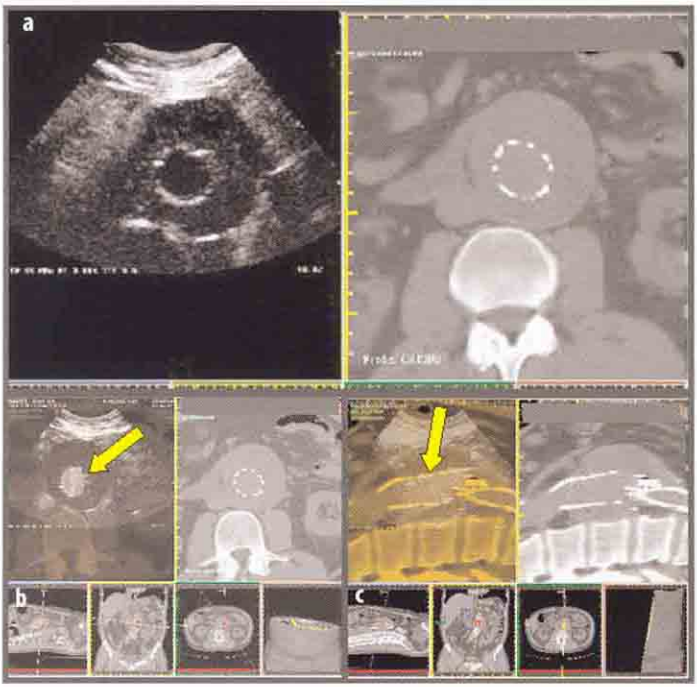

Fig. 17a-c. *Abdominal aortic aneurysm and Fusion Imaging CEUS/CT.* **a** CEUS transversal baseline scan and analogous transversal baseline CT. Transversal (**b**) and longitudinal (**c**) CEUS scan after contrast administration; prosthesis is normally patent (*yellow arrow*) without any signs of endoleak; in the left of the screen there are analogous transversal and longitudinal CT baseline scans

Follow-Up After Embolisation and Guidance for Percutaneous Intervention

Follow-up of percutaneous embolizing treatments of visceral aneurysms is a further interesting field of application for CEUS.

The presence of metallic intravascular coils gives rise to the onset of artefacts in CT and MR images, which may sometimes impair the diagnostic efficacy of these imaging tools. CEUS, on the contrary, is not limited by density artefacts, or by posterior acoustic shadowing artefacts (Fig. 18).

Any persisting flow signal inside the aneurysmatic chamber is detectable with CEUS both in precocious and in late follow-up examinations; the contrast and spatial resolution of the system is high enough to provide a significant diagnostic accurary (Fig. 19).

CEUS may also be used as a guidance tool for interventional procedures in real-time [19].

Once identified and characterised, the type II leakage can be excluded percutaneously through thrombin injection directly into the aneurysmatic sac using an anterior or posterior approach. CEUS permits the entire procedure to be guided in real-time.

In fact, CEUS enables the operator to identify the exact position of the leakage, monitoring of the percutaneous puncture and correct injection of thrombotic agent. Finally, the procedure outcomes are evaluated with CEUS, identifying the persistence of any residual endoleaks and the determination of the timing of subsequent treatments (Fig. 20).

Follow-up of endoleak percutaneous embolisation is facilitated by a fusion imaging system; CT, as a reference technique, demonstrates hyperdense material in place of the previous endoleak, showing the area of maximum interest where CEUS examination should be performed (Fig. 21).

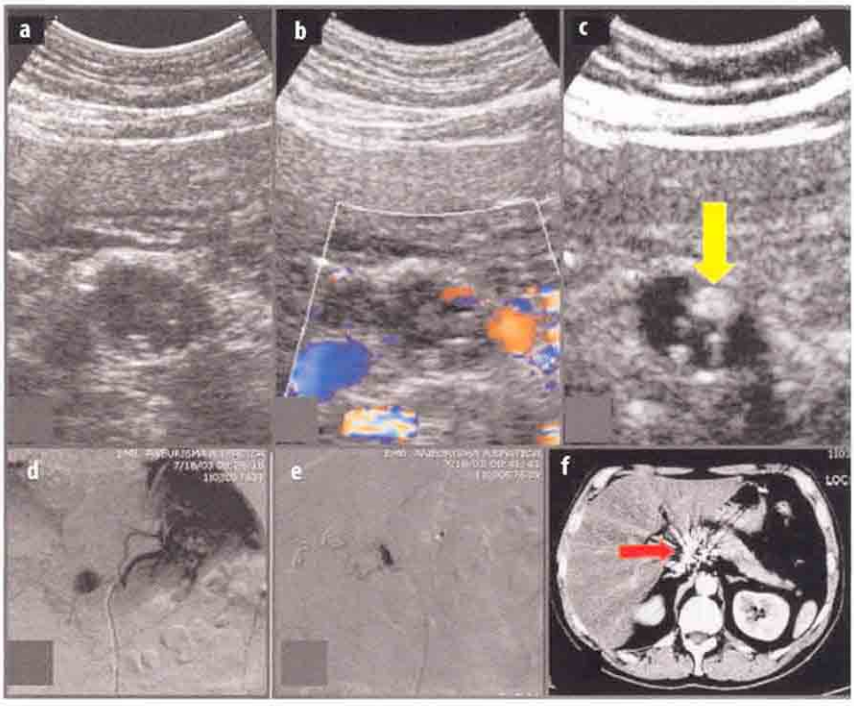

Fig. 18a-f. *Recanalisation of an hepatic artery aneurysm after metallic coil embolisation.* **a, b** Transversal US and CD scan. In B-mode an oval, 2 cm large image, inhomogeneous in echo-texture and with some internal small hyperechoic spots due to metallic coils, is detectable. The corresponding CD scan demonstrates some colour pixels inside the aneurysm (possibly due to artefacts or persisting flow?). **c** CEUS scan. After contrast administration, a small hyperechoic nidus (*yellow arrow*) is detectable inside the aneurysm corresponding to an area of revascularisation. **d-f** DSA and angio-CT. In F, coarse artefacts (*red arrow*) due to metallic coils prevent the correct evaluation of the aneurysm with this technique. DSA: diagnosis (**d**) and post-embolisation control (**e**)

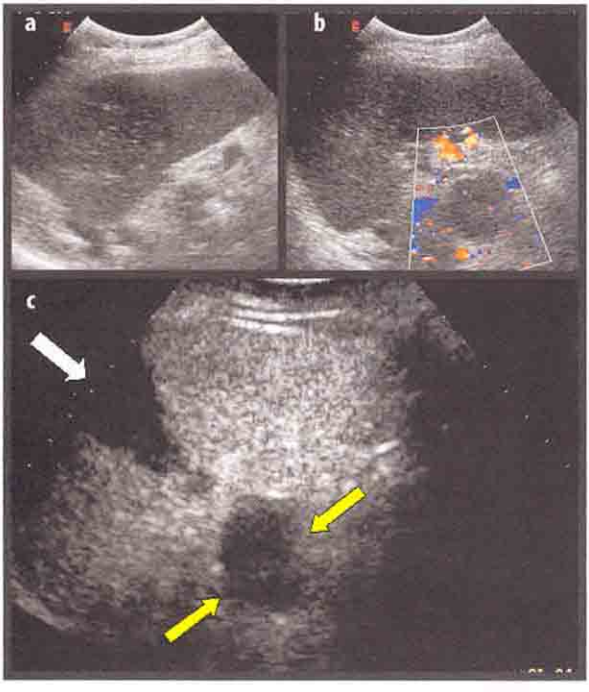

Fig. 19a-c. *Complete embolisation of a splenic artery aneurysm with partial ischemia in the middle third of the spleen.* **a, b** Transversal US and CD scan. In B-mode, an oval image 15 mm large, echo-structured and hypoechoic, is depicted medially to the splenic hilum. **c** CEUS scan. After contrast agent administration, the splenic aneurysm is completely unenhanced because of a complete exclusion (*yellow arrows*); the triangular mesosplenic hypoechoic area with apex directed towards the hilum corresponds to the ischemic lesion (*white arrow*). The remaining splenic parenchyma is homogeneously hyperechoic

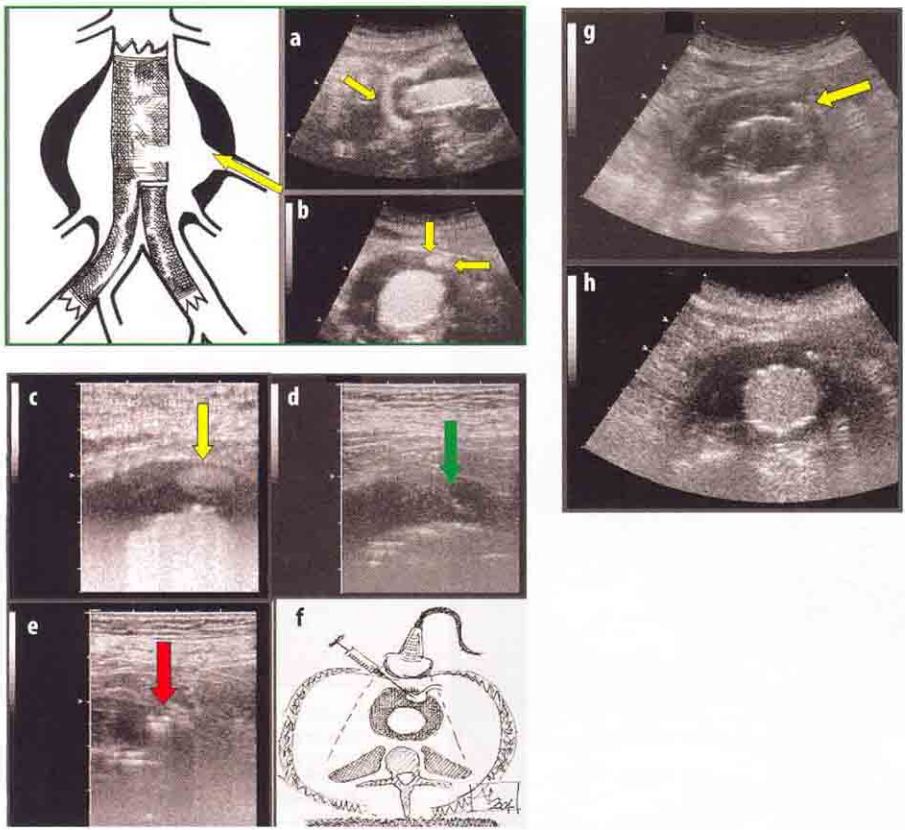

Fig. 20a-h. *CEUS-guided percutaneous exclusion through thrombin injection of a type II endoleak (due to recanalisation of inferior mesenteric artery).* **a, b** Longitudinal and transversal scan, CEUS. A thin flow lumen in the left antero-lateral portion of the thrombus is demonstrated (**a**); in B the site of inflow through the inferior mesenteric artery (*yellow arrows*) is diagnosed. In both scans, the endoprosthesis is normally perfused. **c-f** CEUS combined to B-mode scan (at low MI). In **c**, CEUS shows the precise site of revascularisation characterised by a small hyperechoic area (*yellow arrow*) located in the anterior part of the peripheral thrombus: targeting phase. The prosthesis is normally perfused. Low MI B-mode evaluation (**d**) permits visualisation of the tip of the needle (*green arrow*): puncture phase. Low MI B-mode (**e**) detects multiple hyperechoic spots in the thrombus corresponding to the thrombosing agent selectively injected in the leak (*red arrow*): injection phase. In **f**, the scheme of the procedure performed via an anterior percutaneous approach is depicted. **g, h** Post-procedure B-mode and CEUS examination. B-mode shows some hyperechoic spots (*yellow arrow*) in the left anterior region of the thrombus corresponding to injected thrombin. CEUS (**h**) demonstrates the normal patency of the prosthesis and the absence of contrast agent inside the thrombus, even in the position of the previous endoleak

Particular Situations: Diagnosis of 'Slow' Extraluminal Flows

A particular field of interest is the evaluation of extravascular slow flows in active bleeding [20, 21].

CEUS is less panoramic in comparison to other imaging techniques such as CT, caused by the physical obstacles of air and bone structures; on the other hand, its high spatial and contrast resolution for the representation of contrast agent justifies the important role of the technique in post-traumatic and spontaneous retroperitoneal bleeding, and is thus very frequent nowadays in clinical practice, secondary to antiplatelet and anticoagulant agents (Fig. 22).

In these situations, even at the patient's bedside, CEUS is able to identify any active bleeding and to follow the evolution spontaneously or after embolisation of the collection.

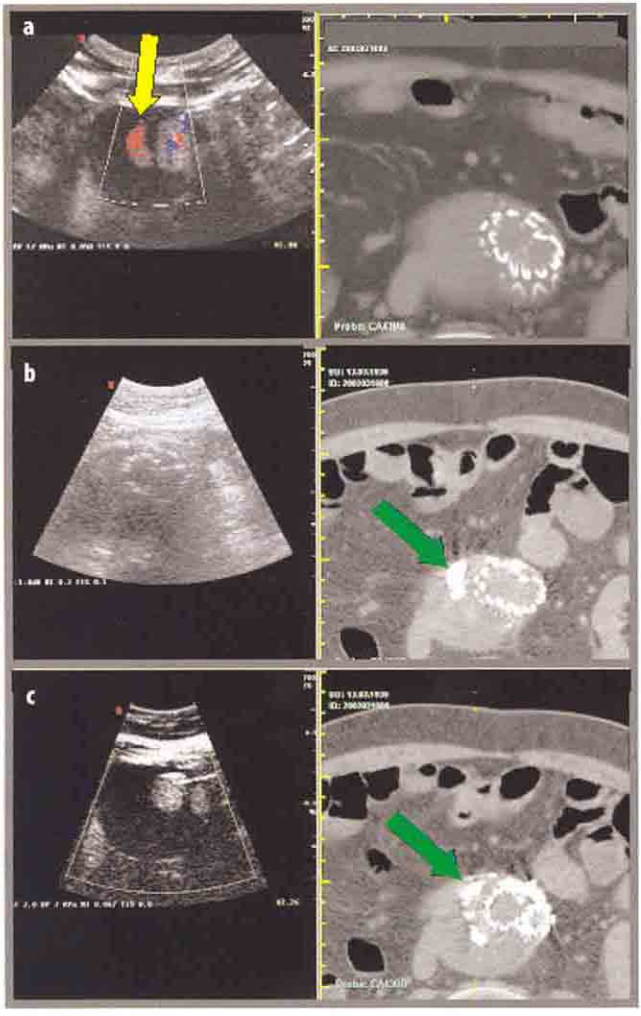

Fig. 21a-c. *Follow-up evaluation after type II endoleak embolisation through CEUS-Low MI CD/CT fusion imaging.* **a** Transversal Fusion CEUS/low MI CD scan combined with CT. **b** Analogous scan after embolisation. CT detects a hyperechoic material corresponding to embolisation materials in the leakage position (*green arrow*); the position corresponds to **a**. **c** Analogous follow-up scan. With CEUS, no sign of leak is detectable; prosthesis is regularly patent. The precision of the follow-up evaluation is guaranteed by the corresponding CT image

Conclusions

The recent introduction of B-mode contrast-specific low MI algorithms (CEUS) has provided a quality of vascular US imaging similar to other imaging techniques such as angio-CT, angio-MR and digital angiography (DSA).

CEUS enables a morphological demonstration of blood flow to be easily obtained, even when the speed of the flow is so reduced as to be undetectable on CD or when movements of anatomical structures around vessels produce colour artefacts.

CEUS is not nephrotoxic or invasive and so it can be performed even at short intervals, in order to help determine the patient's appropriate therapeutic regime.

Patients can be submitted to CEUS not only in a Radiology Department, but anywhere in the hospital (the bedside, Emergency Room, Intensive Care Unit, Surgery).

The diagnostic role of CEUS in vascular studies is limited to a 'segmental' and focused analysis of a specific vascular district, primarily percutaneous aortic prostheses evaluation, because it is burdened with the same limits as US, i.e., a limited panorama.

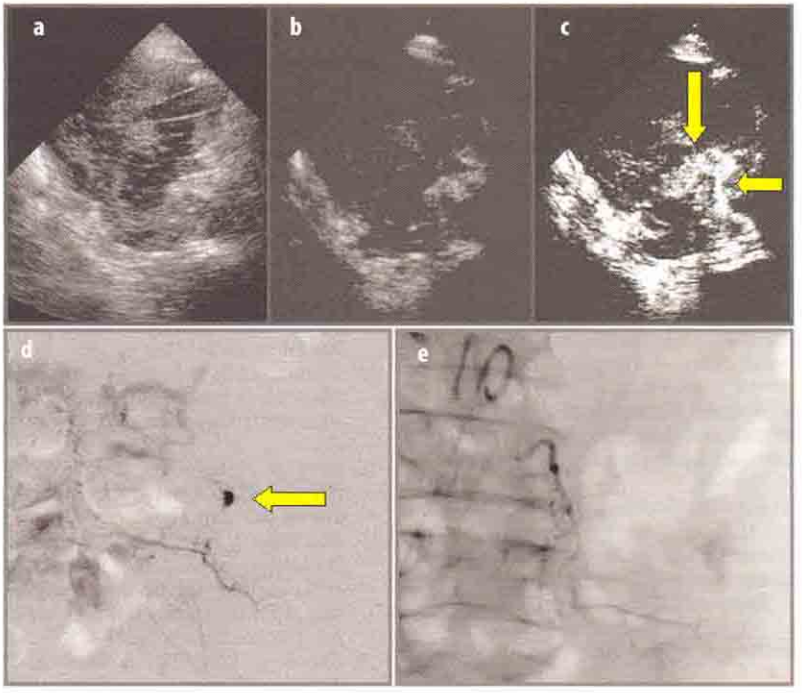

Fig. 22a-e. *Retroperitoneal perfused haematoma.* **a** Left hip transversal scan, B-mode. Expansive inhomogeneous echo-textured lesion with small anechoic internal areas: probable haematoma. **b, c** Left hip transversal scan, CEUS. Comparing to baseline CEUS scan (**b**), in which a complete cancellation of signal coming from steady tissue is obtained, 60 seconds after contrast administration (**c**) inside the haematoma an irregular and hyperechoic image (*yellow arrows*) becomes evident, corresponding to active bleeding. **d, e** DSA. The diagnostic angiography (**d**) shows a small nidus on contrast agent corresponding to active bleeding (*yellow arrow*). After embolisation (**e**), a vascular exclusion of the arterial branch afferent to the active bleeding area is demonstrated

Key Points

- Endoleak is defined as the presence of flow inside the residual peri-prosthesic aneurismatic sac.
- Contrast-enhanced ultrasound (CEUS) enables the demonstration of vascular prosthesis patency.
- The identification of ultrasound contrast agent is not dependent on blood flow velocity; even very slow flows are therefore depicted with CEUS.
- Ultrasound contrast agents are a useful tool for intraprocedural guidance for embolization of visceral aneurysms.

References

1. Taylor KJ, Holland S (1990) Doppler US. Part 1. Basic principles, instrumentation and pitfalls. Radiology 174:297-307
2. Winkler P, Hemke K, Mahl M (1990) Major pitfalls in Doppler investigations. Part II. Low flow velocities and colour Doppler applications. Pediatr Radiol 20:304-310
3. Wachsberg RH (2003) B-flow, a non Doppler technology for flow mapping: early experience in the abdomen. Ultrasound Q 19:114-122
4. Mattrey RF, Pelura TJ (1997) Perfluoro-carbon based ultrasound contrast agents. In: Goldeberg BB (ed) Ultrasound contrast agents. Martin Dunits, London, pp 83-87
5. Morel DR, Schwieger I, Hohn L et al (2000) Human pharmacokinetics and safety evaluation of Sono Vue, a new contrast agent for ultrasound imaging. Invest Radiol 35:80-85
6. Parent FN, Meier GH, Godziachvili V et al (2002) The incidence of type I and II endoleak: a 5-year follow-up assessment with color-duplex ultrasound scan . J Vasc Surg 35:474-481
7. Parodi JC, Palmaz JC, Barone HD (1991) Transfemoral intraluminal graft implantation for abdominal aortic aneurysms. Ann Vasc Surg 5:491-496
8. Parodi JC, Barone A, Piraino R et al (1997) Endovascular treatment of abdominal aortic aneurysms : lessons learned. J Endovasc Surg 4:102-110
9. White GU, Yu W, May J et al (1997) Endoleak as a complication of endoluminal grafting of abdominal aortic aneurysms. J Endovasc Surg 4:152-155
10. Thompson M, Boyle GR, Hartshorn T et al (1998) Comparison of computed thomography and duplex imaging in assessing aortic morphology following endovascular aneurysm repair. Br J Surg 85:340-350
11. Zannetti S, De Rango P, Parente B et al (2000) Role of duplex scan in endoleak detection after endoluminal abdominal aortic aneurysm repair. Eur J Vasc Endovasc Surg 19:531-535
12. Raman KG, Missig-Carroll N, Richardson T et al (2003) Color-flow duplex ultrasound scan versus computed tomographic scan in the surveillance on endovascular anerysm repair. J Vasc Surg 38:645-651
13. Lookstein RA, Goldman J, Pukin L et al (2004) Time-resolved magnetic resonance angiography as a noninvasive method to characterize endoleaks: initial results compared with conventional angiography. J Vasc Surg 39:27-33
14. McWilliams RG, Martin J, White D et al (1999) Use of contrast-enhanced ultrasound in follow up after endovascular aortic aneurysm repair. J Vasc Interv Radiol 10:1107-1114
15. Giannoni MF, Palombo G, Sbarigia E et al (2003) Contrast-enhanced ultrasound imaging for aortic stent-graft surveillance. J Endovasc Ther 10:208-217
16. Bendick PJ, Bove PG, Long GW (2003) Efficacy of ultrasound contrast agents in the non-invasive follow up of aortic stent grafts. J Vasc Surg 37:381-385
17. Golzarian J, Murgo S, Dussaussois L et al (2002) Evaluation of abdominal aortic aneurysm after endoluminal treatment: comparison of color-Doppler sonography with biphasic helical CT. AJR Am J Roentgenol 178:623-628
18. Napoli V, Bargellini I, Sardella SG et al (2004) Abdominal aortic aneurysm: contrast-enhanced US for missed endoleak after endoluminal repair. Radiology 233:217-225
19. Paulson EK, Kliewer MA, Hertzberg BS et al (1995) Color Doppler sonography of groin complications following femoral artery catheterization. AJR Am J Roentgenol 165:439-444
20. Liu JB, Merton DA, Goldberg BB et al (2002) Contrast-enhanced two and three-dimensional sonography for evaluation of intra-abdominal hemorrage. J Ultrasound Med 21:161-169
21. Goldberg BB, Merton DA, Liu JB et al (1998) Evaluation of bleeding site with a tissue-specific sonographic contrast agent: preliminary experiences in an animal model. J Ultrasound Med 17:609-616